

# PEPTIC ULCER DISEASE

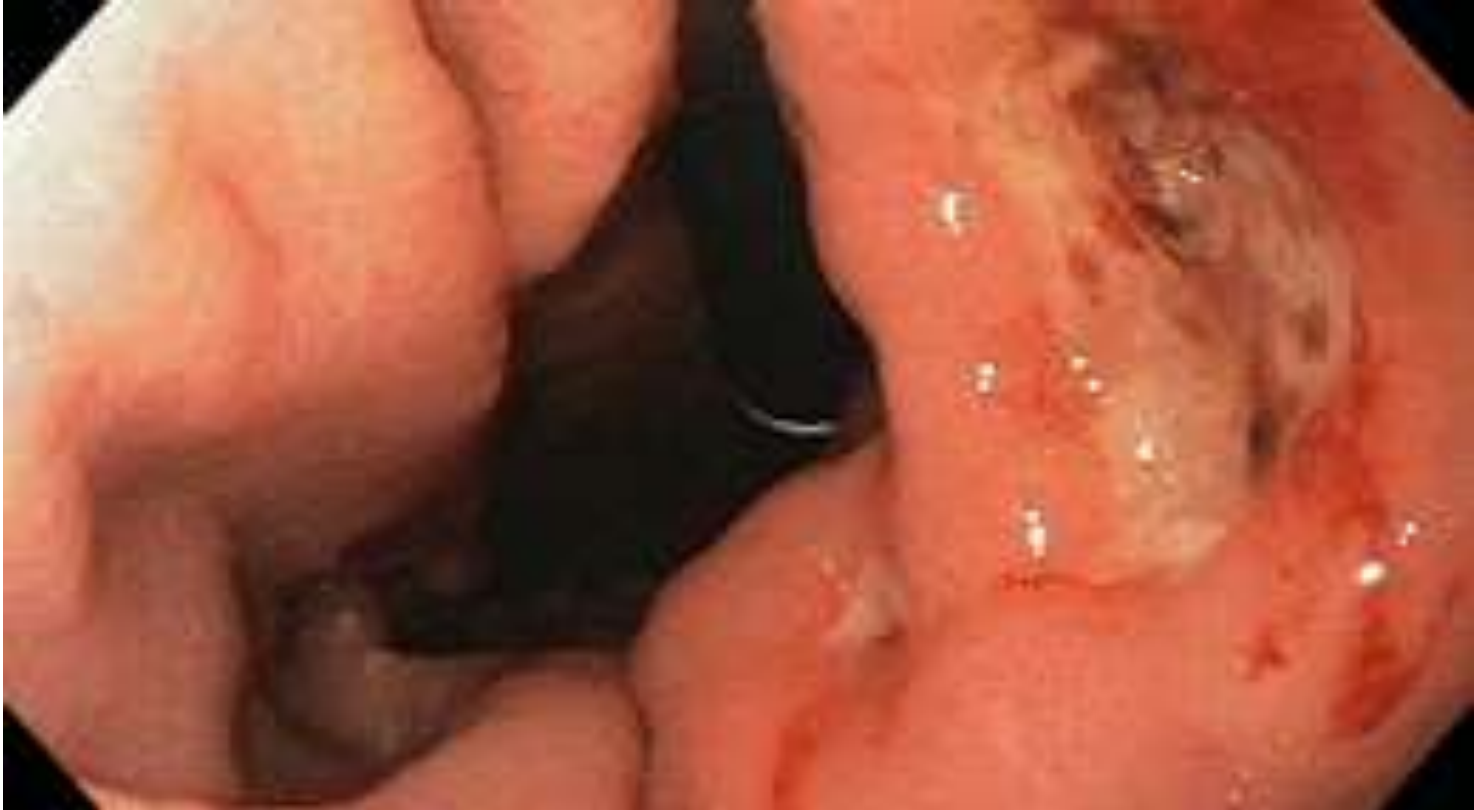Erwin Budi Cahyono

# Objectives

---

- Definition of peptic ulcer
- Comparison of duodenal & gastric ulcers
- Aetiology
- Clinical presentation
- Management
- Emergency scenario

# What is a peptic ulcer?



# Peptic ulcer

---

- A break in superficial epithelial cells penetrating down to muscularis mucosa

# Differences between duodenal & gastric ulcers?

	DUODENAL	GASTRIC
INCIDENCE		
ANATOMY		
DURATION (acute/chronic)		
MALIGNANCY		

# Duodenal vs Gastric

	<b>DUODENAL</b>	<b>GASTRIC</b>
INCIDENCE	More common	Less common
ANATOMY	First part of duodenum – anterior wall	Lesser curvature of stomach
DURATION	Acute or chronic	Chronic
MALIGNANCY	Rare	Benign or malignant

# Taking a history I



- What risk factors would you ask about in the history?

# Risk factors

- ❑ HELICOBACTER PYLORI
- ❑ Non Steroidal Anti-inflammatory Drugs
- ❑ Steroid therapy
- ❑ Smoking
- ❑ Excess alcohol intake
- ❑ Genetic factors
- ❑ Zollinger Ellison syndrome – rare syndrome caused by gastrin-secreting tumour
- ❑ Blood group O
- ❑ Hyperparathyroidism



# H Pylori

- Urease producing, gram negative bacillus
- Developing countries
- Infection increases with age
- Infects mucosa of stomach > inflammatory response > gastritis > increased gastrin secretion > gastric metaplasia > damage to mucosa > ulceration
- Increased risk of developing gastric adenocarcinoma

# Taking a history II



- Take a focused history

# Taking a history

- 55 yr old man presents with a 6-month history of worsening epigastric pain described as a burning sensation. He notices the pain is worse when he is hungry. He feels nauseated with the pain but has not vomited. There is no change in his bowel habits and his weight is more or less stable. He smokes 10 cigarettes a day and drinks socially. He has been to see his GP who has suggested ranitidine but this has not helped. On examination he is tender in his epigastrium but examination is otherwise unremarkable.

# Differential diagnoses for epigastric pain

- Surgical
  - ▣ Biliary colic, acute cholecystitis
  - ▣ Pancreatitis
  - ▣ Perforation of viscus
  - ▣ Acute appendicitis
  - ▣ Malignancy
- Medical
  - ▣ GORD
  - ▣ MI
  - ▣ PE
  - ▣ Pneumonia

# Symptoms of PUD

- Asymptomatic
- Epigastric pain
- Nausea
- Oral flatulence, bloating, distension and intolerance of fatty food
- Heartburn
- Pain radiating to the back

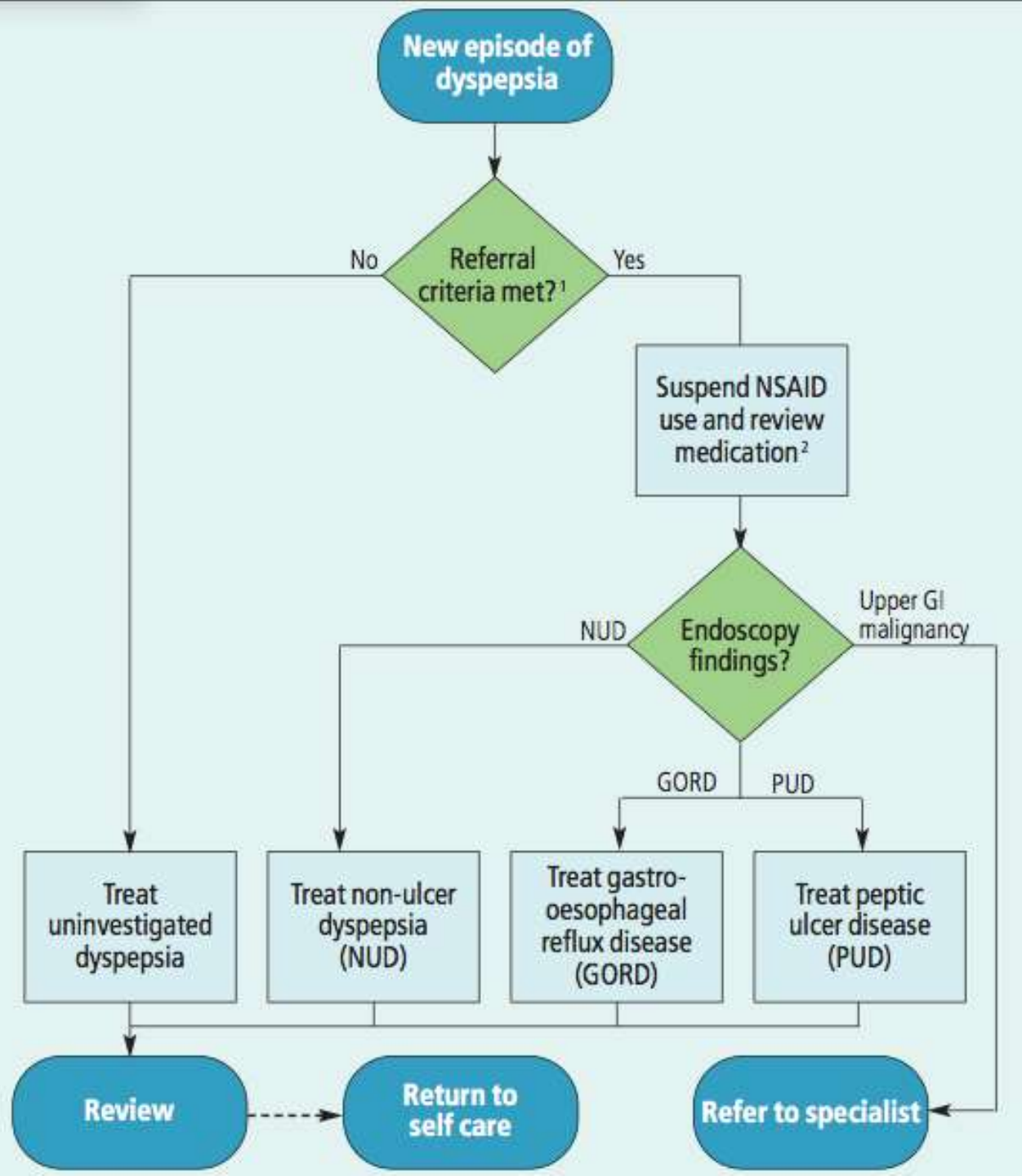
# ALARM signs for epigastric pain

- Chronic GI bleeding
- Iron-deficiency anaemia
- Progressive unintentional weight loss
- Progressive dysphagia
- Persistent vomiting
- Epigastric mass
- Patients aged 55 years and older with unexplained and persistent recent-onset dyspepsia alone

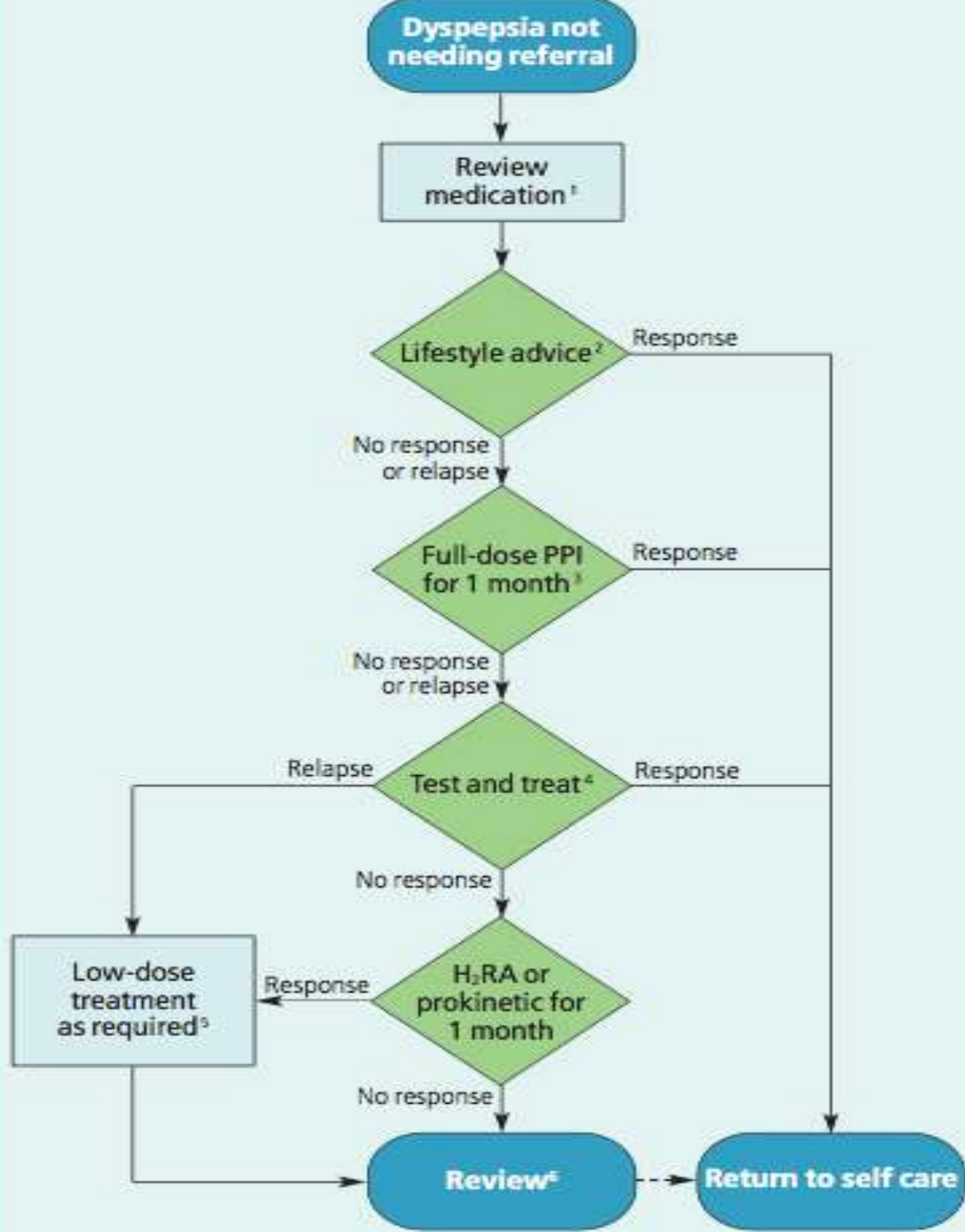
# Management of dyspepsia

---

- NICE guidance for dyspepsia







# Investigations

---

- H pylori testing

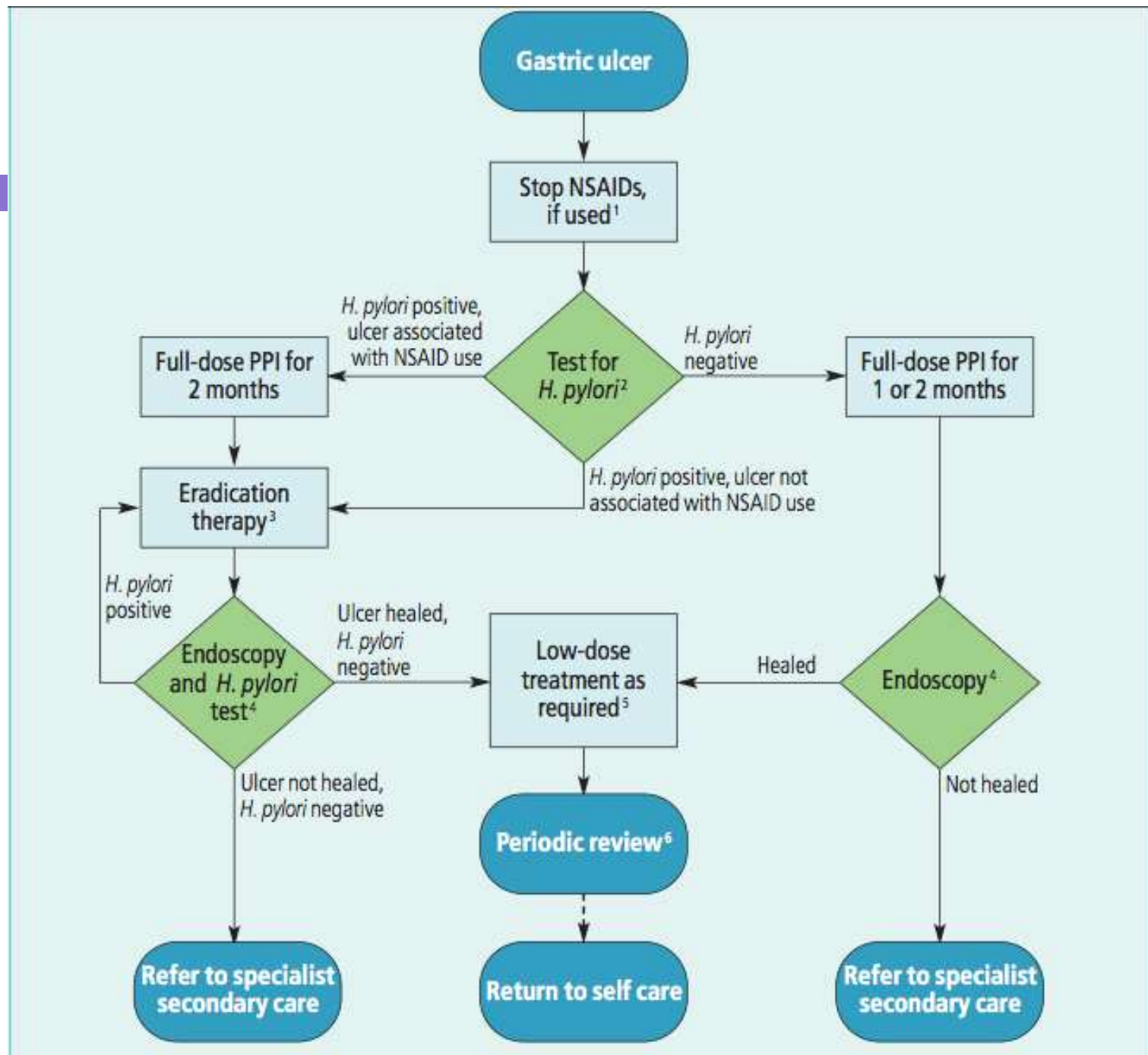
# H pylori testing

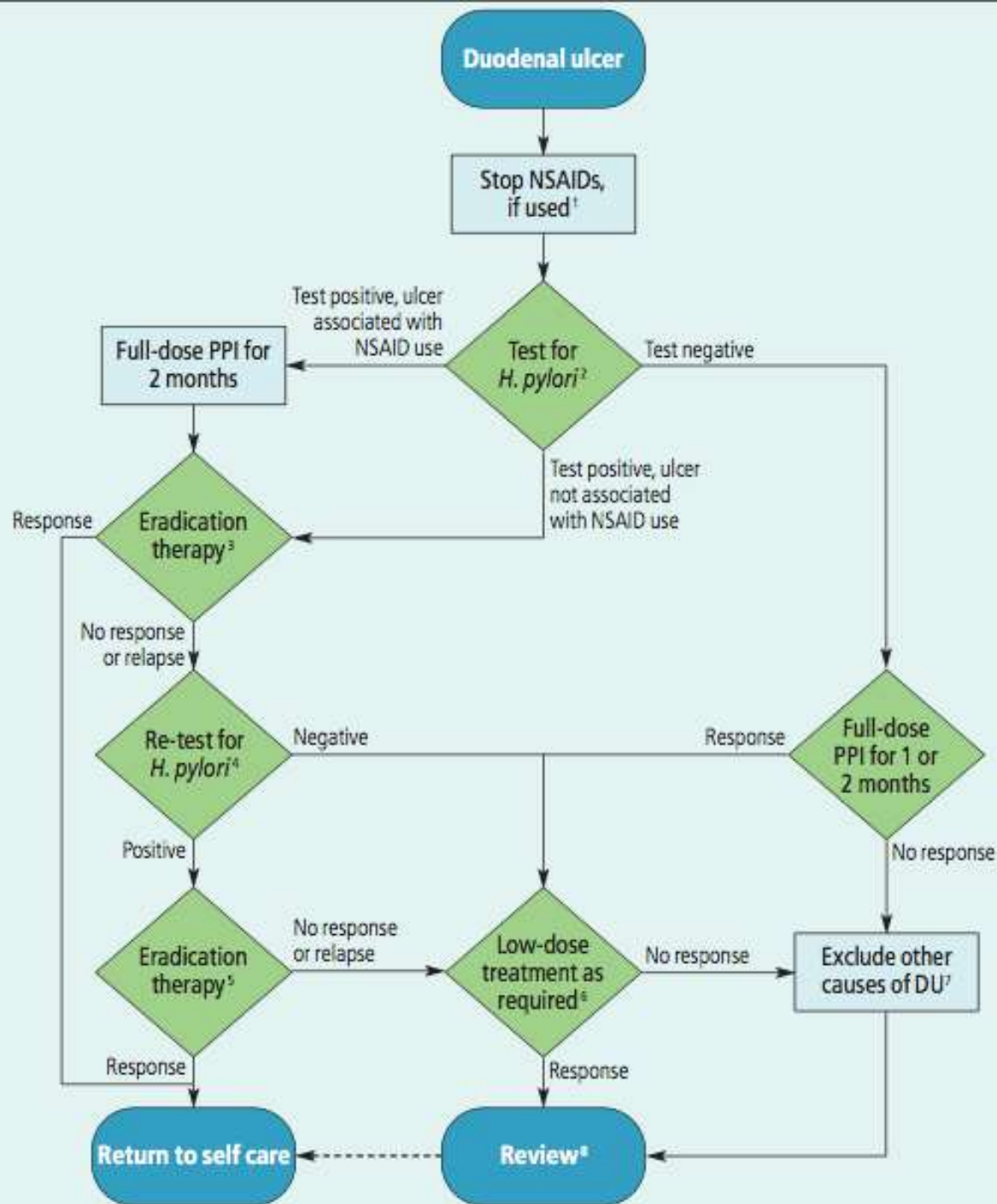
---

- C urea breath tests
- Stool antigen tests
- Serology
- Endoscopy with biopsy

# H pylori treatment

- 7-day, twice-daily
- Use a PPI, amoxicillin, clarithromycin 500 mg (PAC500) regimen or a PPI, metronidazole, clarithromycin 250mg(PMC250)regimen.
- Do not re-test even if dyspepsia remains unless there is a strong clinical need.





# Emergency scenario

- A 50 year old man is brought into A+E via ambulance. He is vomiting bright red blood and complaining of abdominal pain. You get a quick history from his wife who explains he suffers with heartburn and is on lansoprazole. He was out with his work mates last night and drank quite heavily.

# Initial Management I

---

- ABCDE approach
- Call for help



# Initial management II

- Airway is clear
- Breathing – RR 30 breaths/min, Sats 91% OA
- Circulation – HR 130 beats/min, BP 80/40 mmHg
  - ▣ Protect airway & keep NBM
  - ▣ High flow oxygen
  - ▣ Gain access – 2 large bore cannulae
  - ▣ Bloods- FBC, U&Es, LFTs, glucose, clotting, cross match 6 units
  - ▣ Catheterise to monitor urine output

# Initial management III

- If shocked prompt volume replacement
- Either colloid or crystalloid solutions
- Red cell transfusion should be considered after loss of 30% of the circulating volume
- Correct any clotting abnormalities
- Urgent endoscopy after resuscitation

# Acute upper GI bleed

- Common, 10% mortality
- Common causes: PUD, varices
- Endoscopy: primary diagnostic investigation & allows for treatment
- Assess using the Blatchford score at first assessment and full Rockall score after endoscopy

# Rockall score

	Score				
Variable	0	1	2	3	
Age	<60 years	60-79 years	≥80 years		Initial score criteria
Shock	'no shock', SBP' ≥100 mm Hg, pulse <100 beats per minute	'tachycardia', SBP≥100 mm Hg, pulse ≥ 100 beats per minute	'hypotension', SBP <100 mm Hg.		
Comorbidity	no major comorbidity		cardiac failure, ischaemic heart disease, any major comorbidity	renal failure, liver failure, disseminated malignancy	
Diagnosis	Mallory-Weiss tear, no lesion identified and no SRH	all other diagnoses	malignancy of upper GI tract.		Additional criteria for full score
Major stigmata of recent haemorrhage (SRH)	none, or dark spot only		blood in upper GI tract, adherent clot, visible or spurting vessel		

# Summary

- A peptic ulcer is a break in superficial epithelial cells penetrating down to muscularis mucosa
- Duodenal > gastric ulcers
- Can be asymptomatic
- H pylori is a predominant risk factor
- H pylori diagnosed by c urea breath test, stool antigen or if validated serology, treated with PAC500 or PMC250 regime
- Complications of PUD can lead to acute emergency of upper GI bleed