PEMERIKSAAN RADIOLOGI

TRAKTUS DIGESTIVUS

DIVISI RADIOLOGI GASTROINTESTINAL

Anatomi Traktus Digestivus

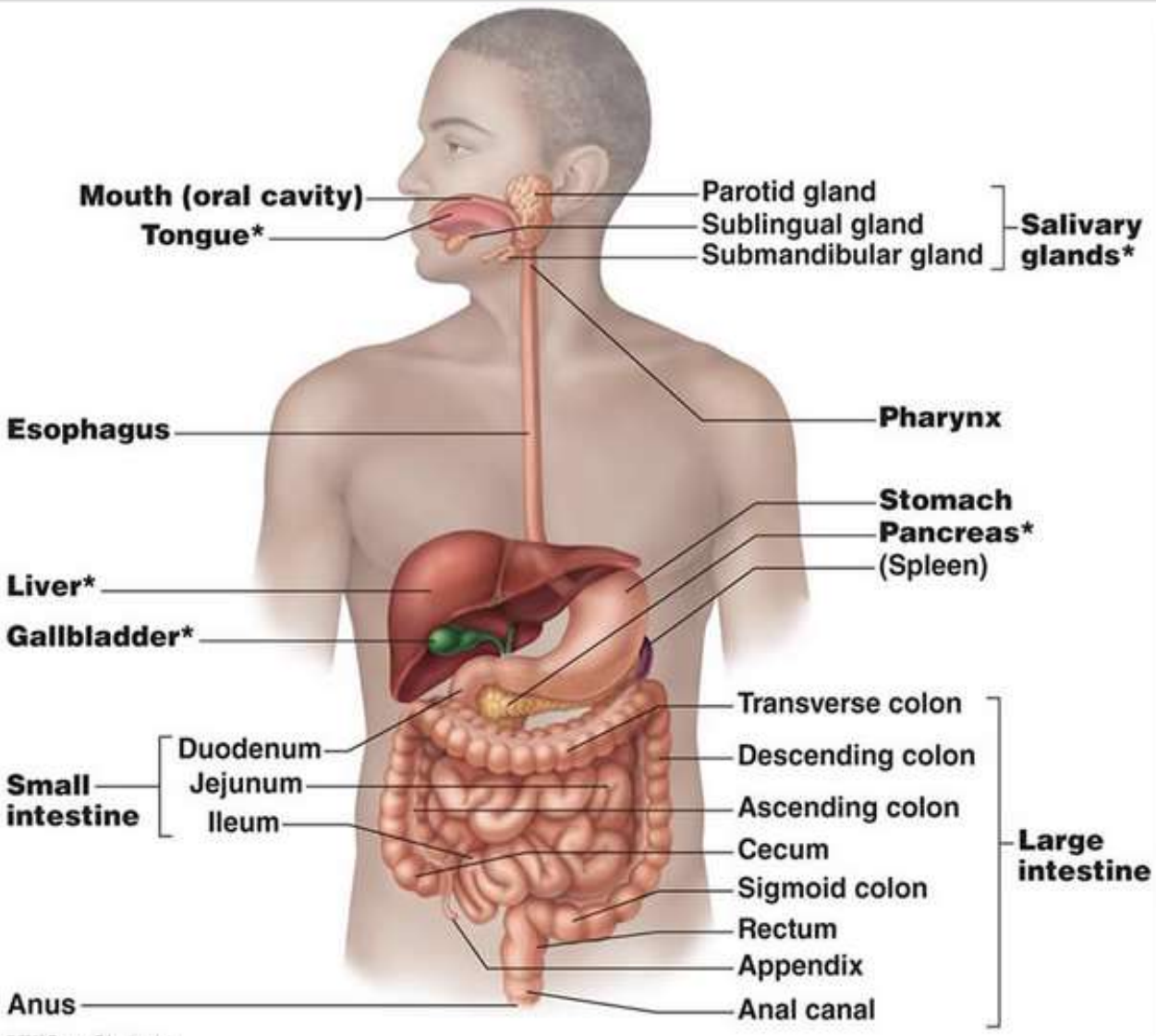

FOTO POLOS

- Foto polos abdomen (FPA / BNO)
  - 1 Posisi : AP
  - 2 Posisi : AP + LLD / AP + Lateral
  - 3 Posisi : AP + LLD + erect / semi erect

Pemeriksaan dengan kontras

- Sialografi
- Esofagografi
- Barium Meal
- Barium follow through
- Lopografi
- Barium enema / colon in loop
- Cholangiografi
- Endoscopic retrograde cholangio pancreatography (ERCP)

Pemeriksaan Radiologi

- Ultrasonografi
- Computed Tomography (CT Scan)
- Magnetic Resonance Imaging (MRI)
- Kedokteran nuklir

X Ray

- Organ padat, menyerap sinar → opaq (putih) pada film
  contoh : tulang, batu
- Organ yang tidak padat, meneruskan sinar → luscent (hitam) pada film.
  contoh : udara dalam usus, udara intraperitoneal

Foto Polos Abdomen AP (Supine)

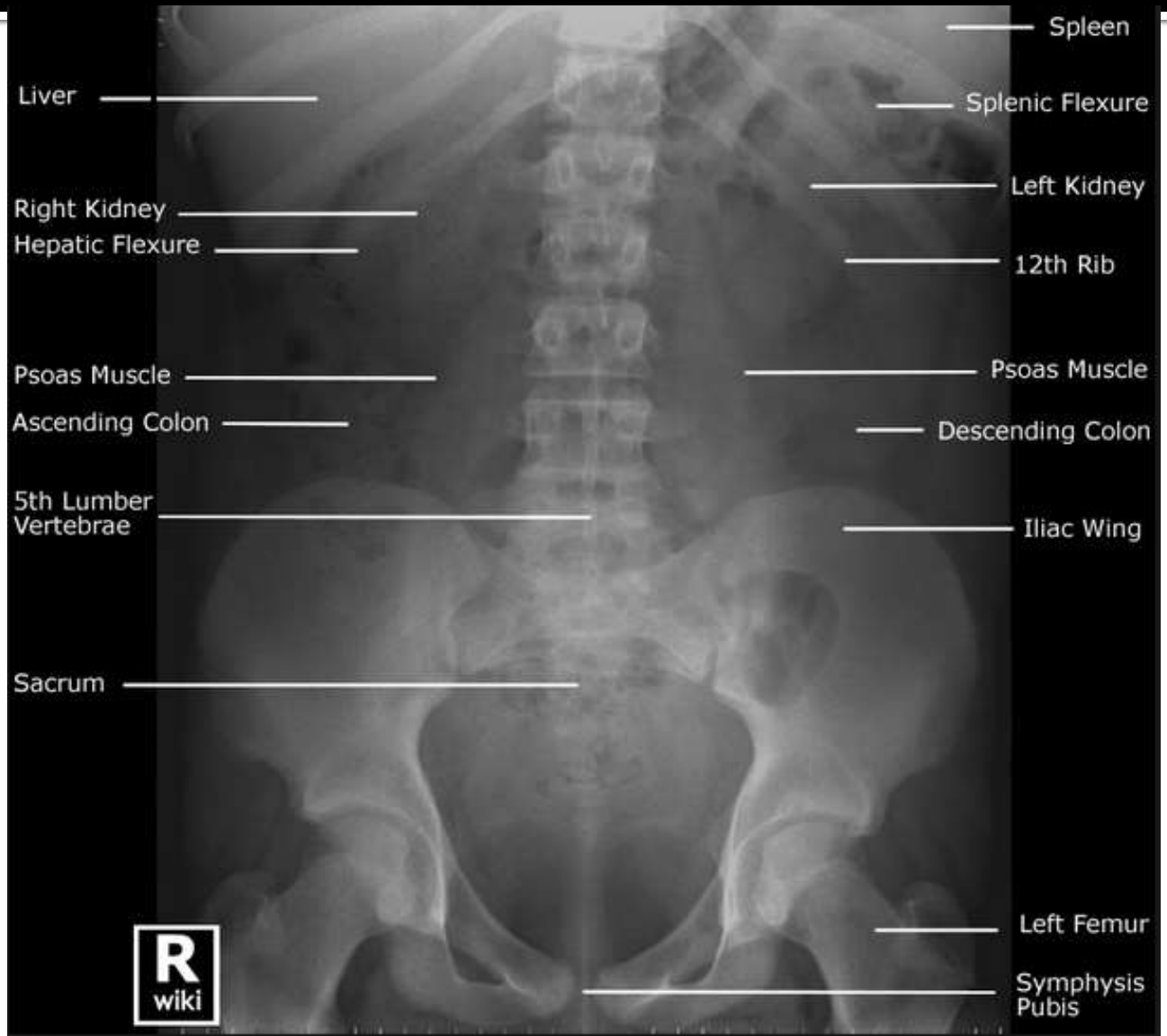

Foto Polos Abdomen LLD

Foto Polos Abdomen Erect

PNEUMOPERITONEUM

FOTO POLOS ABDOMEN

Pneumoperitoneum

- Pneumoperitoneum adalah gambaran udara bebas pada intraperitoneal / kavum peritoneum
- Normal : udara tidak terdapat pada kavum peritoneum, retroperitoneal, dinding usus, maupun sistem bilier
- Penyebab : perforasi organ berongga, trauma iatrogenik, trauma tumpul abdomen, setelah proses pembedahan abdomen, manipulasi transperitoneal, needle biopsi

Pneumoperitoneum

SUBDIAFRAGMATIC GAS

- Adanya udara / free air dibawah diafragma kanan maupun kiri
- Paling sering karena perforasi GI →60 – 80 % kasus pneumoperitoneum
- Terlihat pada X- foto thorax maupun abdomen posisi erek
- Minimal udara 5 cc

Pneumoperitoneum

CUPOLA SIGN :
Gambaran lusensi bentuk arkuata yang melapisi permukaan vertebra thorakal bawah dan diproyeksikan pada bagian bawah jantung

Pneumoperitoneum

CONTINOUS DIAFRAGMA SIGN :

- Terdapat free air yang banyak dibawah diafragma, struktur asli dari diafragma yang kontinyu akan dapat terviasualisasi.
- Ditemukan pada kasus pneumoperitoneum masif

Pneumoperitoneum

Free air dibawah diafragma kiri yang overlapping dengan udara dalam struktur fundus gaster

Pneumoperitoneum

DECUBITUS ABDOMEN SIGN

- udara bebas akan menempati titik tertinggi → gambaran lusen antara dinding abdomen dan hepar
- cukup sensitif → bisa untuk mengkonfirmasi berbagai gambaran yang mirip
- Pasien perlu ditempatkan dalam posisi ini selama 10 menit

Pneumoperitoneum

RIGLER'S SIGN

- gambaran dimana dua sisi dari dinding bowel dapat tervisualisasi pada foto polos abdomen
- double wall sign atau gas relief sign atau serosal sign
- tanda ini tidak terlalu sensitif, dan akan muncul apabila volume free air mencapai 1 liter (moderate)

Pneumoperitoneum

TRIANGLE SIGN

- area lusensi bentuk triangular diantara loop – loop usus
- free air terjebak diantara 3 loop usus yang berdekatan, atau diantara 2 loop usus dan peritoneum parietal
- tidak spesifik, namun sensitifitasnya sangat tinggi
- Lokasi paling sering :lateral bawah abdomen

Pneumoperitoneum

LIGAMENTUM FALCIFORME SIGN

- Normal → tidak terlihat sebagai struktur yang terpisah dari hepar
- Free air →pita vertikal dari soft tissue yang paralel dengan batas kanan korpus vertebra
- Jumlah besar free air dan tidak sensitif

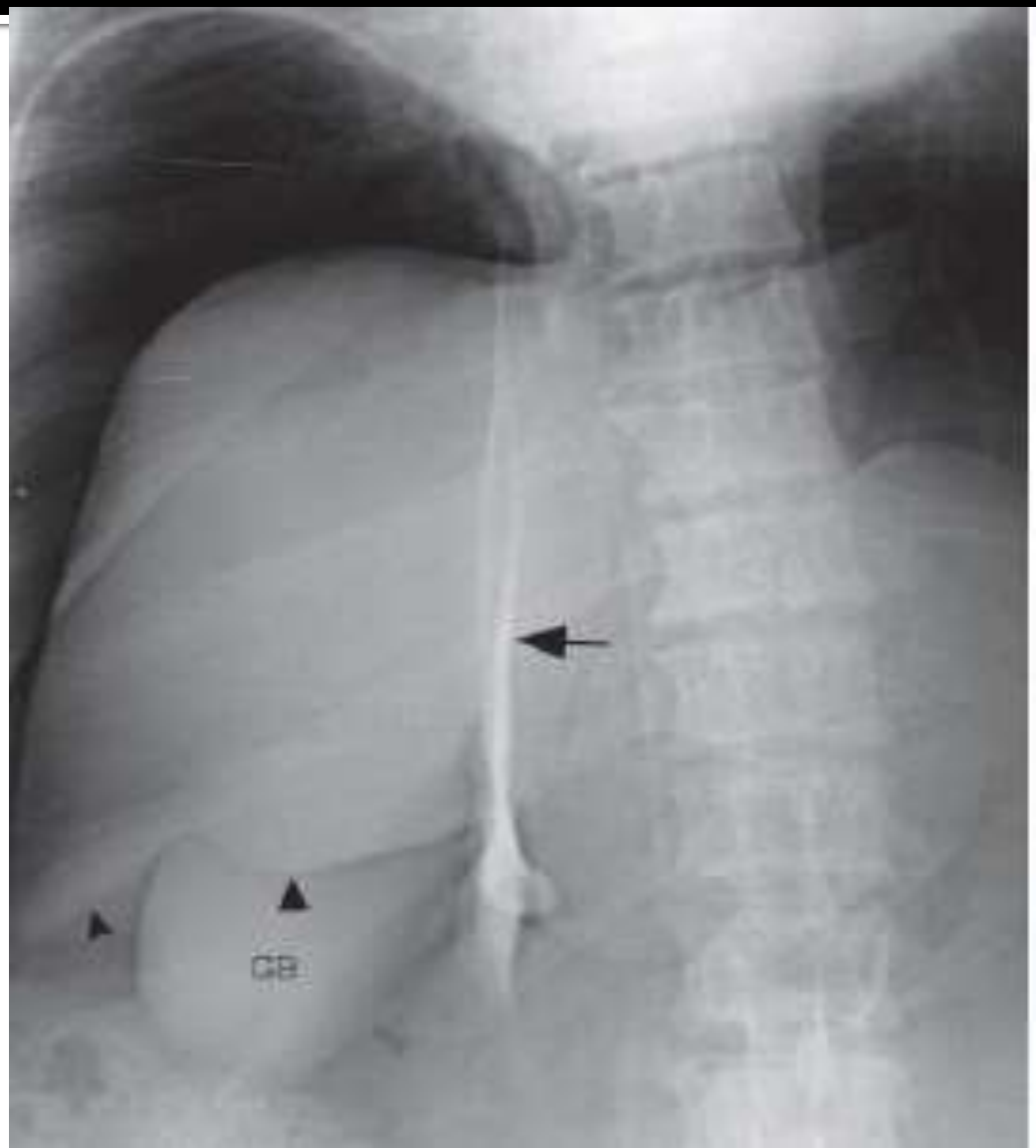

Pneumoperitoneum

FOOTBALL SIGN

- bayangan bentuk oval besar yang membatasi tepi perifer kavum peritoneum
- Sering pada bayi
- 2 % kasus pneumoperitoneum pada dewasa
- menyerupai bentuk oval besar dari American football
- → pneumoperitoneum masif

DILATASI USUS

Dilatasi usus halus & usus besar

	Usus Halus	Kolon
Haustra	-	+
Valvula conniventes	+	–
Jumlah loop	>>>>	<<<<
Letak loop	Sentral	Perifer
Radius curvatura loop	Kecil	Besar
Diameter lumen	30-50mm	> 50 mm
Massa feses	-	+

Obstruksi Usus Halus

Supine



LLD

Erect

Obstruksi Usus Besar

- BNO supine

ILEUS PARALITIK

Causes of Adynamic Ileus
Intra-abdominal disorders–Appendicitis, pancreatitis, peritonitis, immediate postsurgical period, etc.
Nonabdominal disorders–Pneumonia, MI, head trauma
Systemic disorders–Electrolyte disorders (hypokalemia), sepsis
Medications–Opiates, anticholinergics
Bed-bound debilitation

Pemeriksaan Radiologi dengan Kontras

Sialografi

- Pemeriksaan kel ludah submandibula dan kel Parotis.
- Menggunakan kontras media water soluble yang dimasukkan melalui muara saluran kel ludah.
- Ind: batu, stenosis, tumor

Sialografi

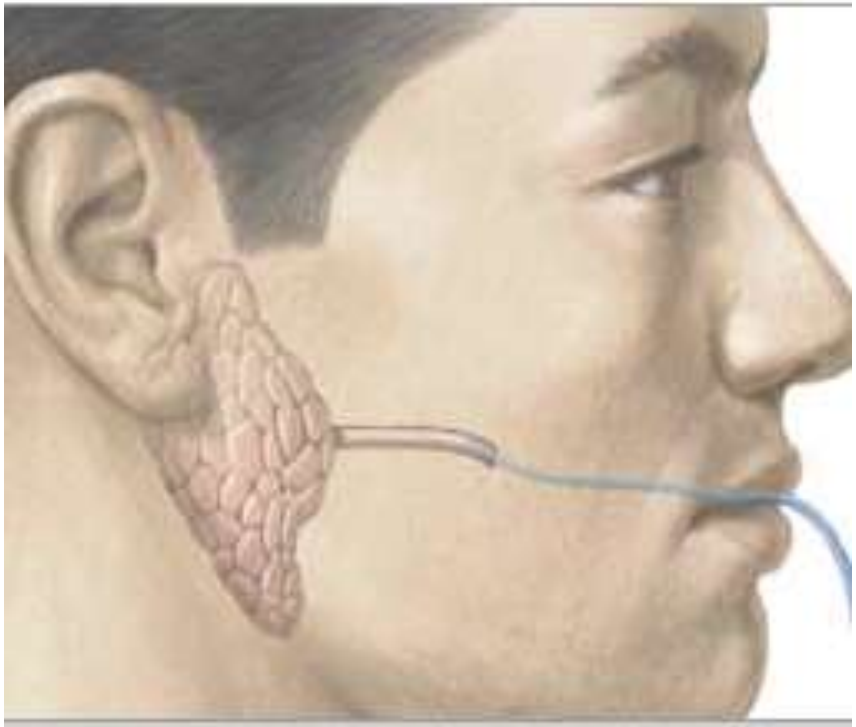

Contrast medium is injected into the salivary gland duct

Barium Meal (OMD)

- Upper GI Study
  - Barium ($BaSO_4$)
  - Water Soluble
- Esofagografi
- Oesophagus Maag Duodenum (OMD)

Barium Meal

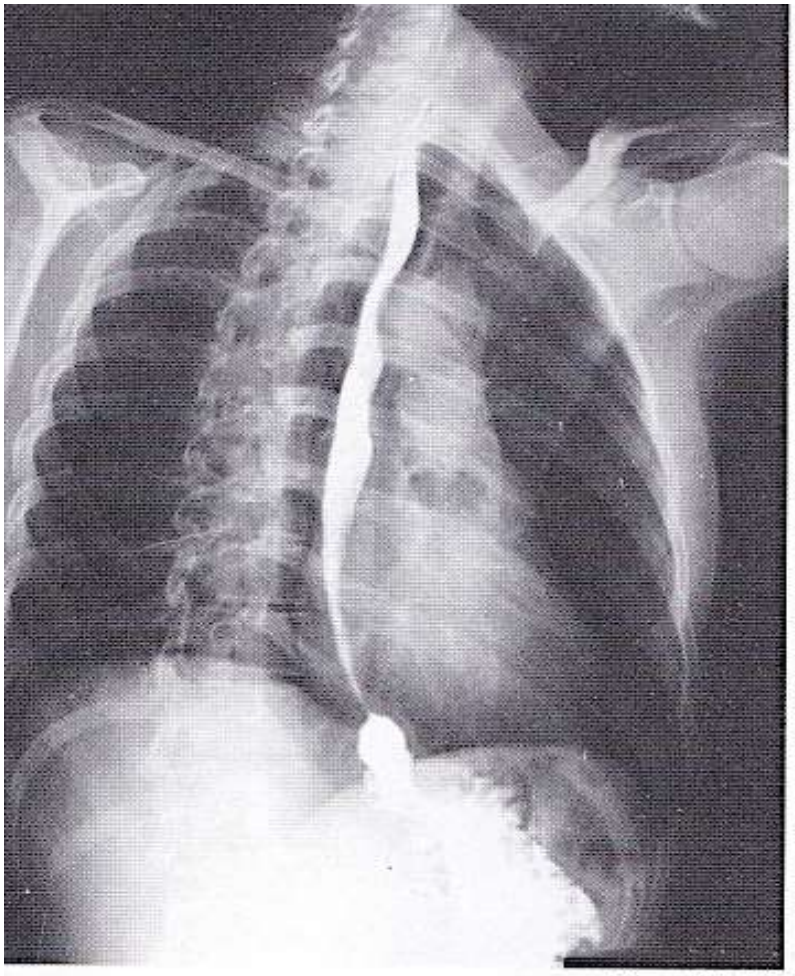

Fig. 14-63

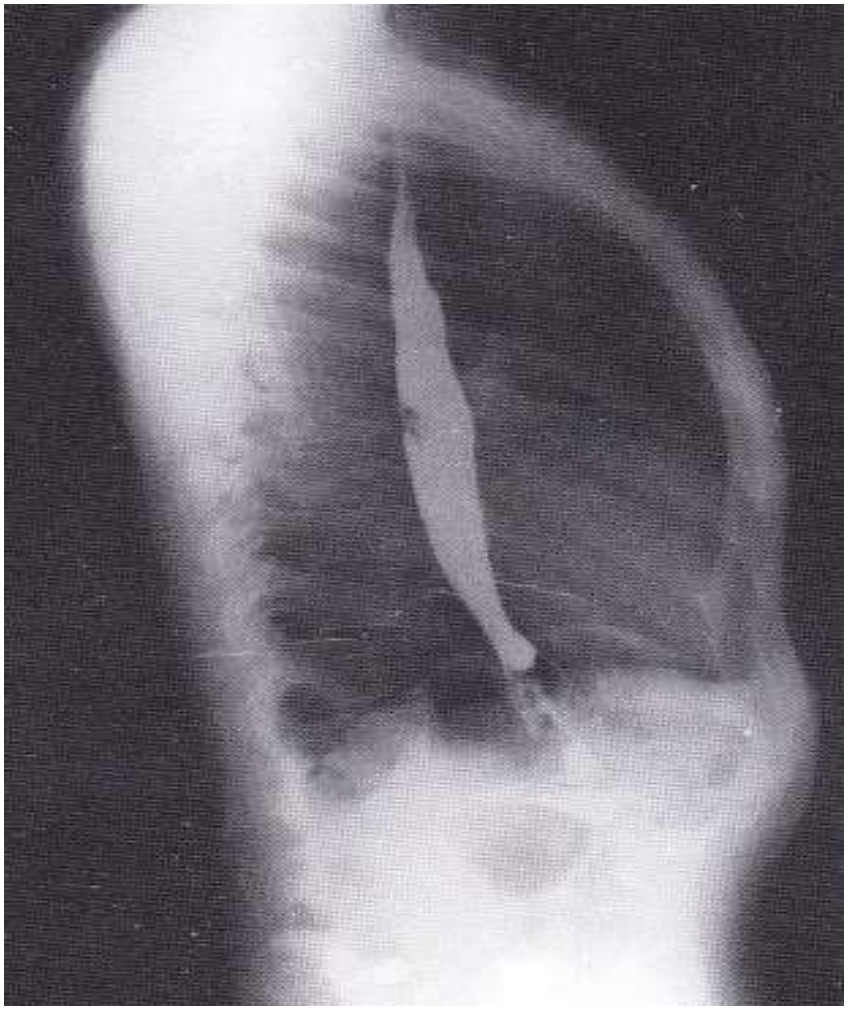

Barium Meal (OMD)

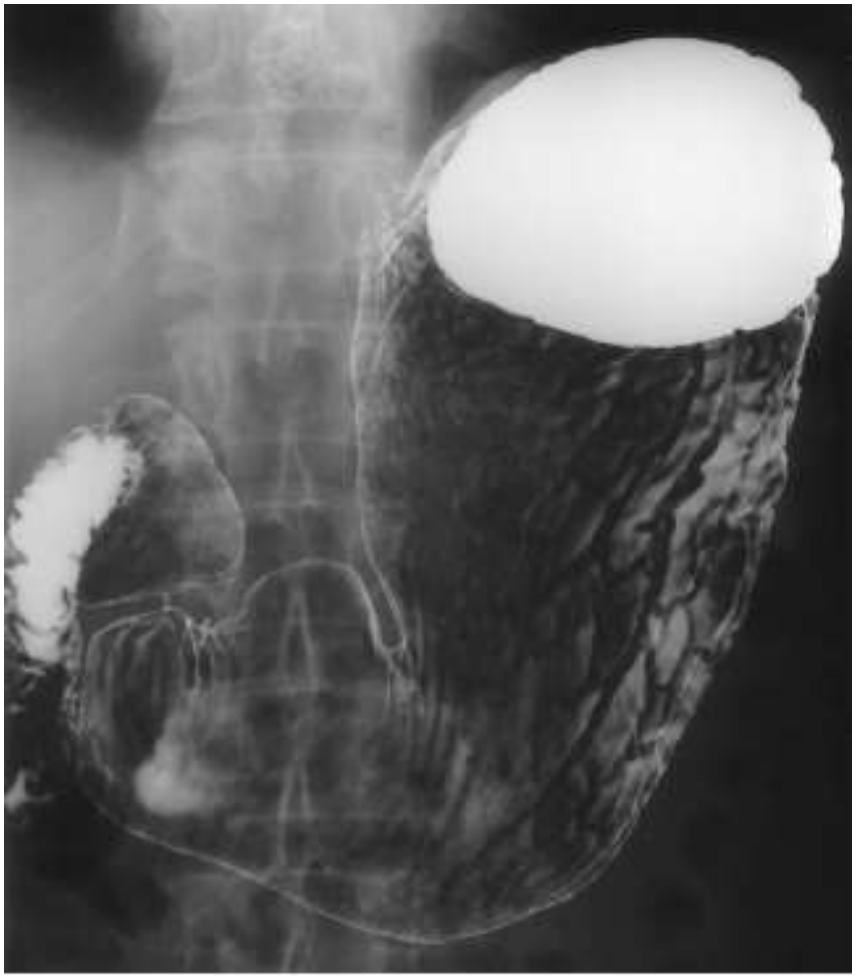

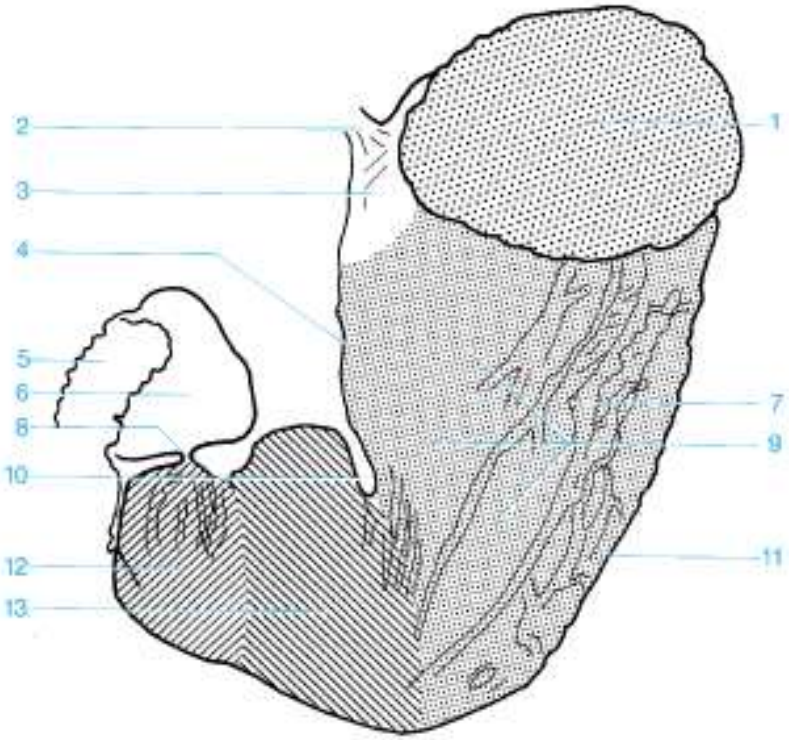

1 Fundus
2 Abdominal esophagus
3 Cardia
4 Lesser curvature
5 Duodenum
6 Ampulla of Vater
7 Gastric folds (posterior wall)
8 Pylorus
9 Body of the stomach
10 Angular notch
11 Greater curvature
12 Pyloric antrum
12 + 13 Antrum

Barium Meal (OMD)

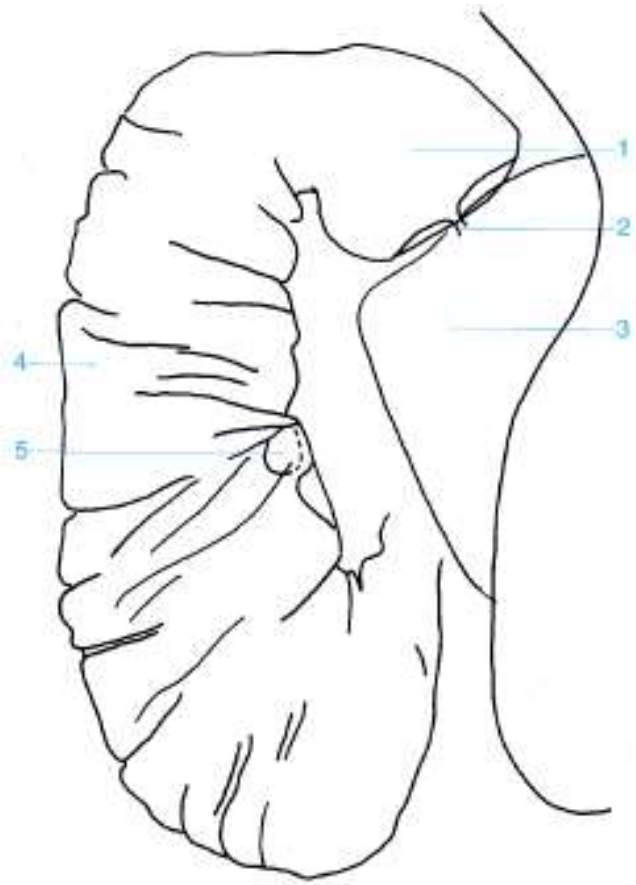

1 Ampulla of Vater
2 Pylorus
4 Descending duodenum
5 Papilla of Vater

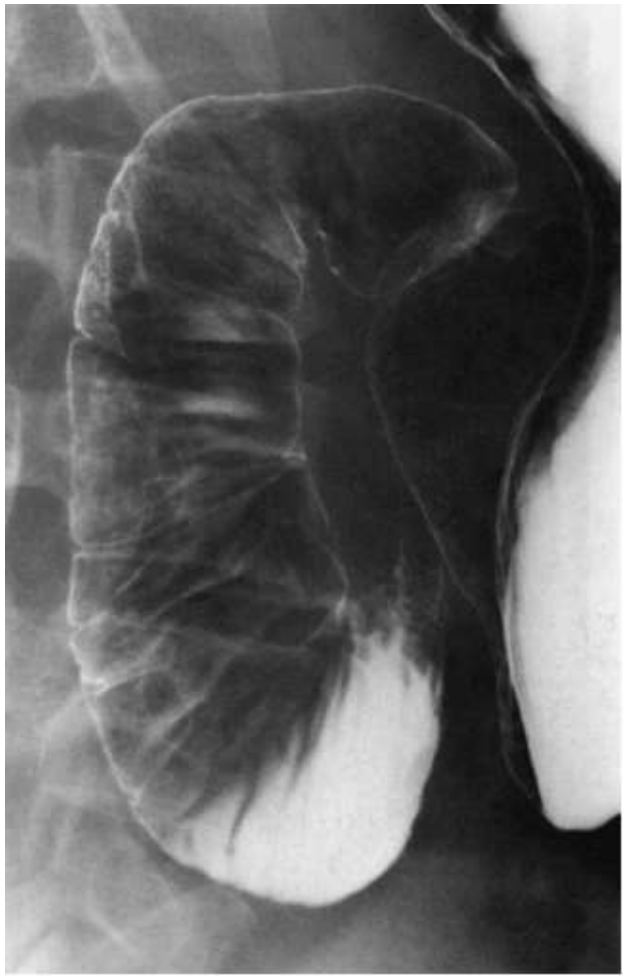

Barium Meal (Akalasia)

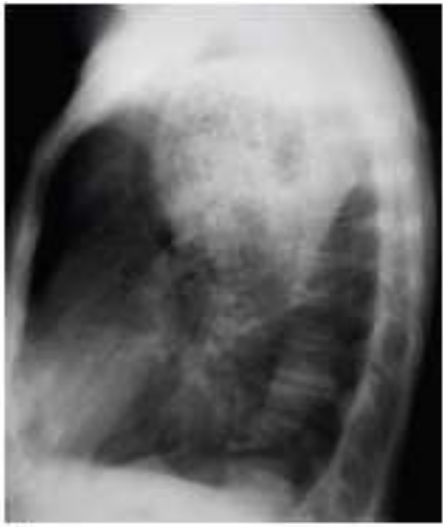

c

d

Fig. 912a The distended esophagus filled with remnants of food and air in this patient with achalasia is prominent up to the upper mediastinum. **b** The lateral projection of the chest displays the food impaction in the esophagus and the anteriorly displaced trachea with even greater clarity. **c** After the administration of oral contrast medium, the grossly dilated proximal esophagus and the narrowed ganglion depleted segment are outlined. This finding is also called the "bird's beak." **d** A little imagination helps, of course.

Ca Esofagus

Esophagram shows polypoid mass of distal esophagus with irregular surface and luminal narrowing. Squamous cell carcinoma.

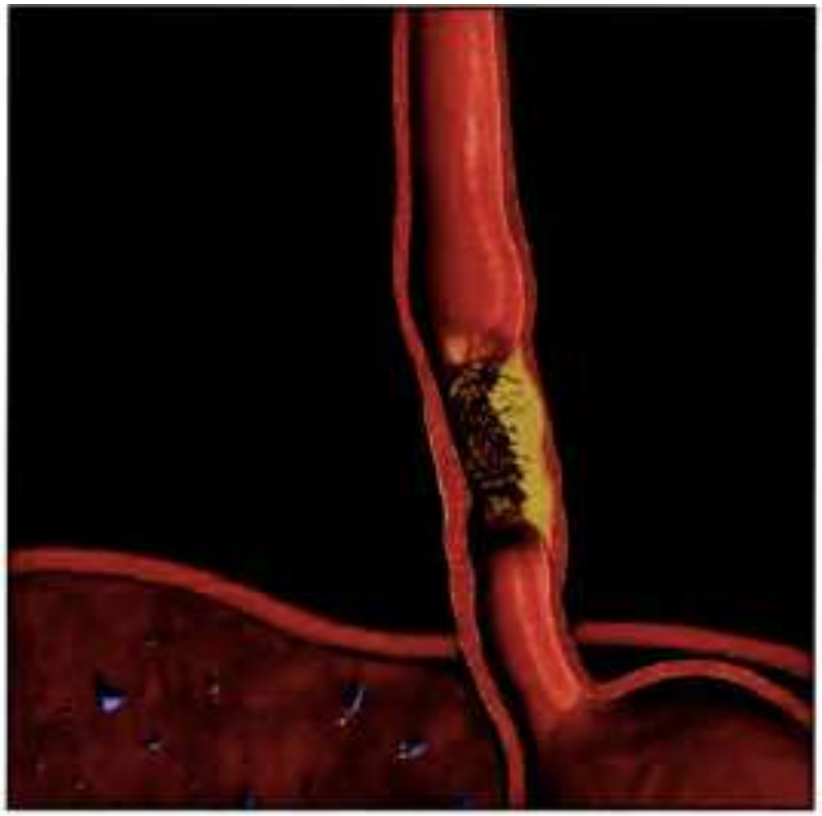

Graphic shows sessile polypoid mass with irregular surface that infiltrates the esophageal wall and narrows the lumen.

Varises Esofagus

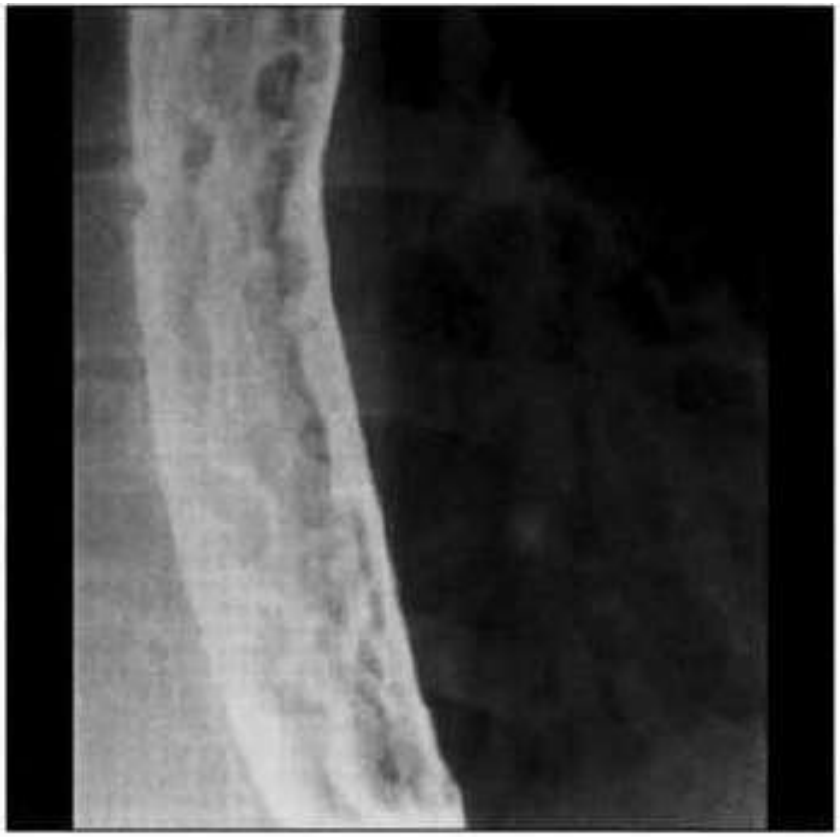

Double-contrast esophagram shows tortuous, nodular longitudinal "folds" typical of varices.

Graphic shows dilated, tortuous, submucosal collateral veins (varices).

Barium Follow Through

- Small bowel study
- Barium ($BaSo_4$)
- Periodik imaging

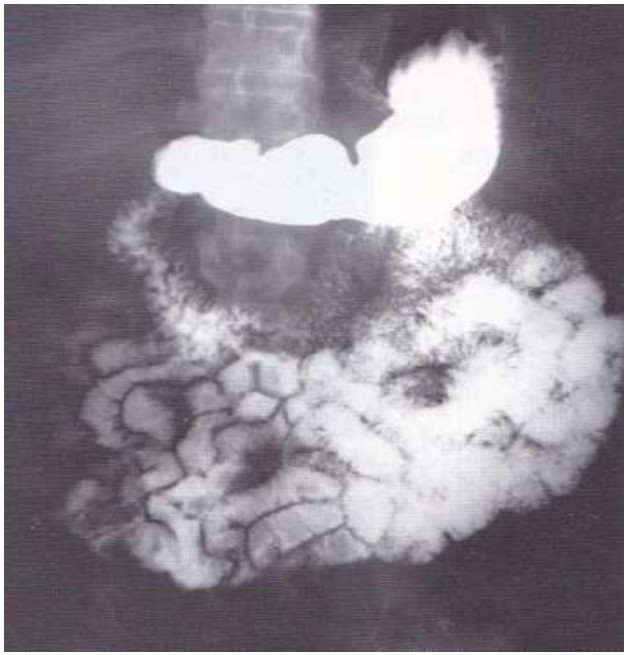

Barium Follow Through

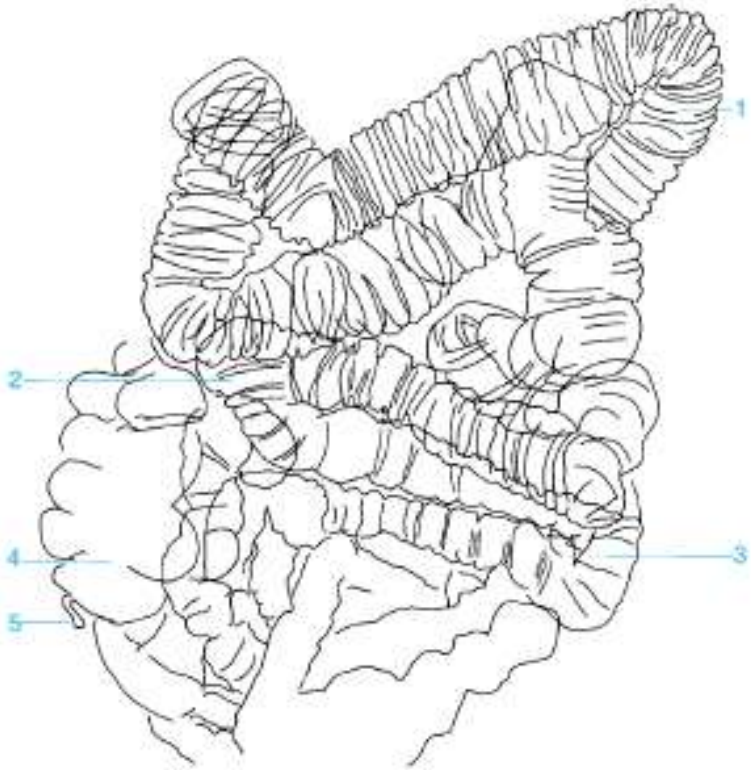

1 Jejunum
2 Junction of the ileum and jejunum
3 Ileum
4 Cecum
5 Appendix

Barium Enema (Colon In Loop)

Kontras Tunggal

Barium Enema (Colon In Loop)

- Lower GI Study
  - Barium ($BaSo_4$)
  - Water Soluble

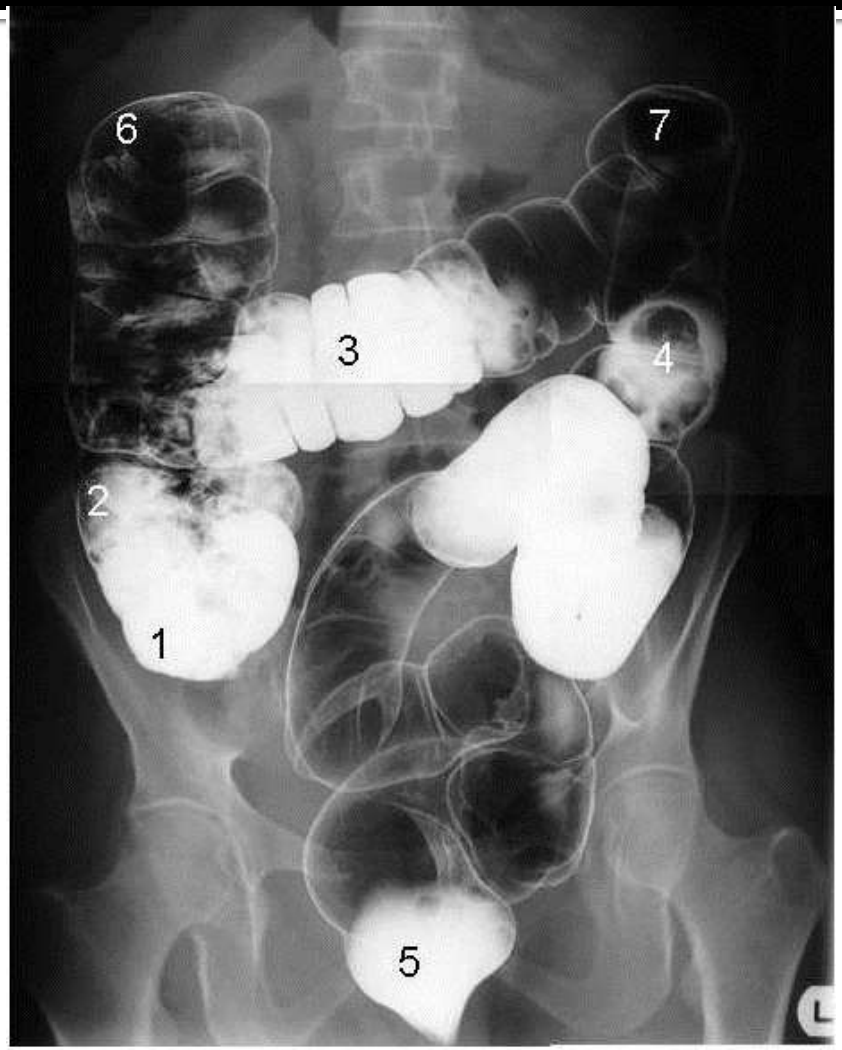

Kontras Ganda

Colon In Loop (Ca Colon)

Colon In Loop (Colitis)

Colon In Loop (Divertikel)

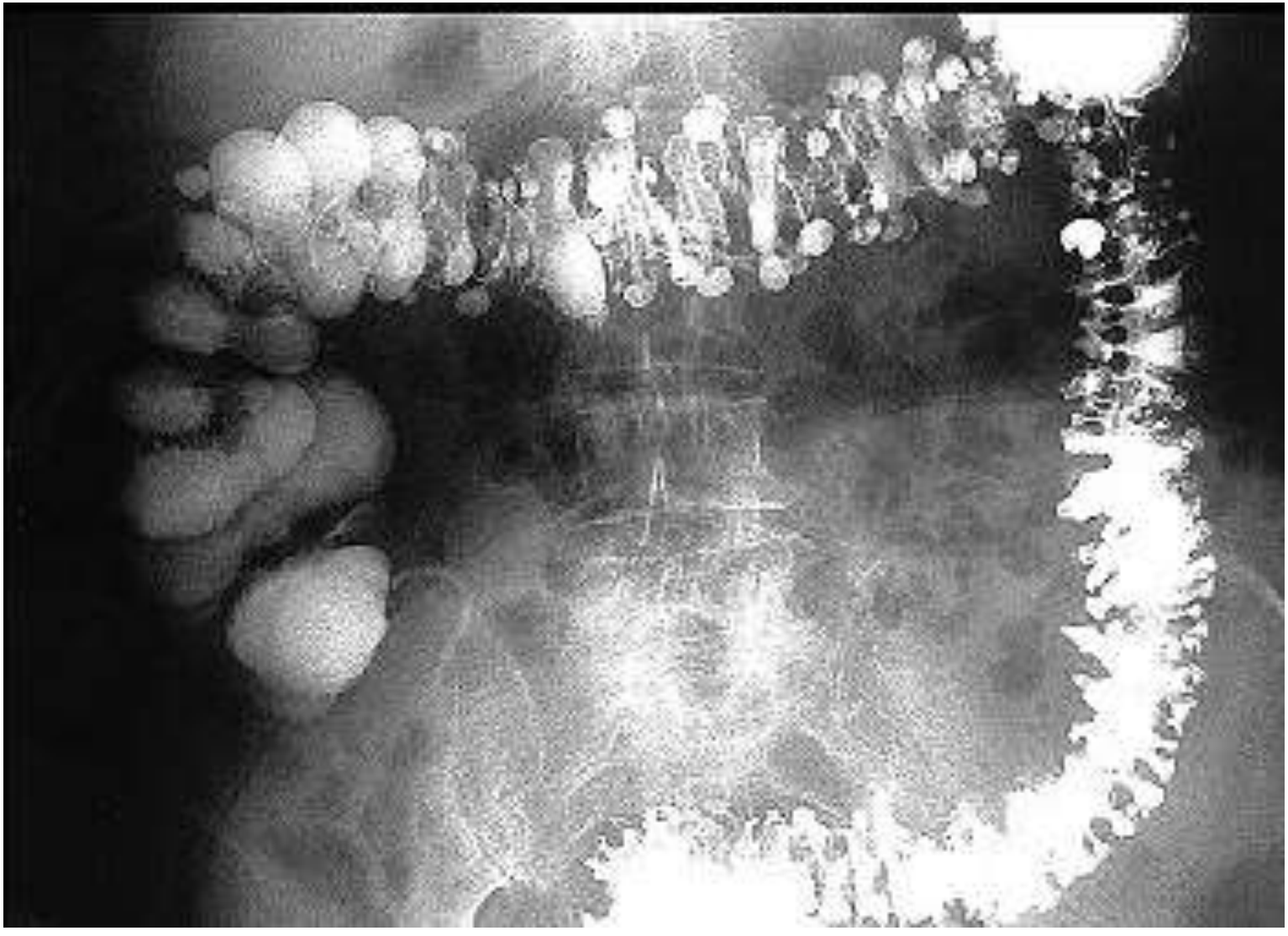

Colon In Loop (Divertikel vs Polip)

Cholangiografi vs ERCP

- Cholangiografi

- ERCP

Ultrasonografi (USG)

- Menggunakan gelombang ultrasonik
- Tidak invasif, aman, relatif murah, cepat
- Tidak memerlukan persiapan khusus
- Tampak jelas: hepar, bilier, pankreas, lien, ren, ascites
- Cairan → gelombang suara diteruskan, tidak dapat dipantulkan : anechoic
  Padat → gelombang suara dipantulkan : hiperechoic

Ultrasonografi Hepar Normal

A

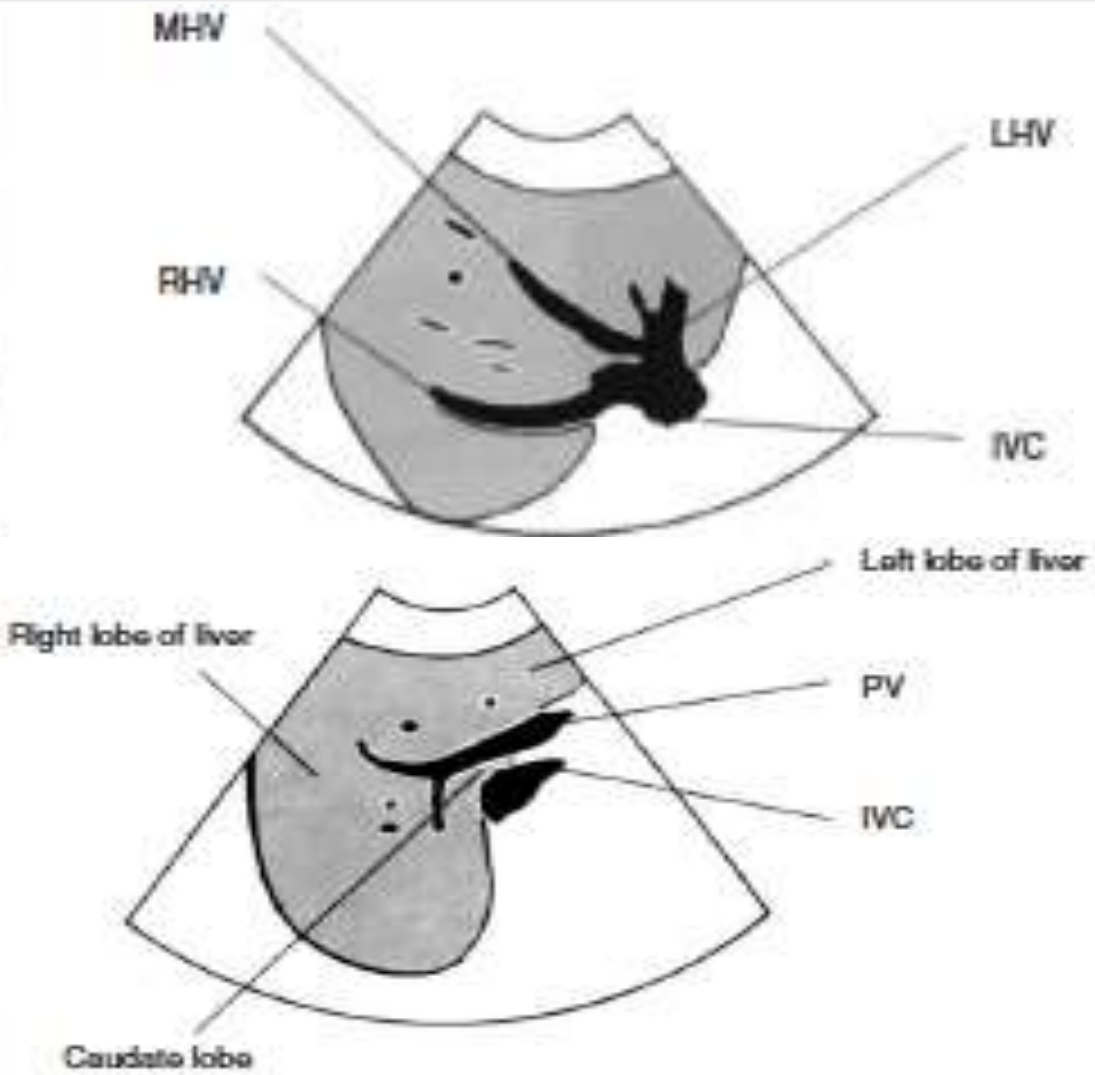

B

Ultrasonografi Hepar (Nodul)

Ultrasonografi Hepar (Nodul)

Ultrasonografi Hepar (Sirosis)

Ultrasonografi (USG)

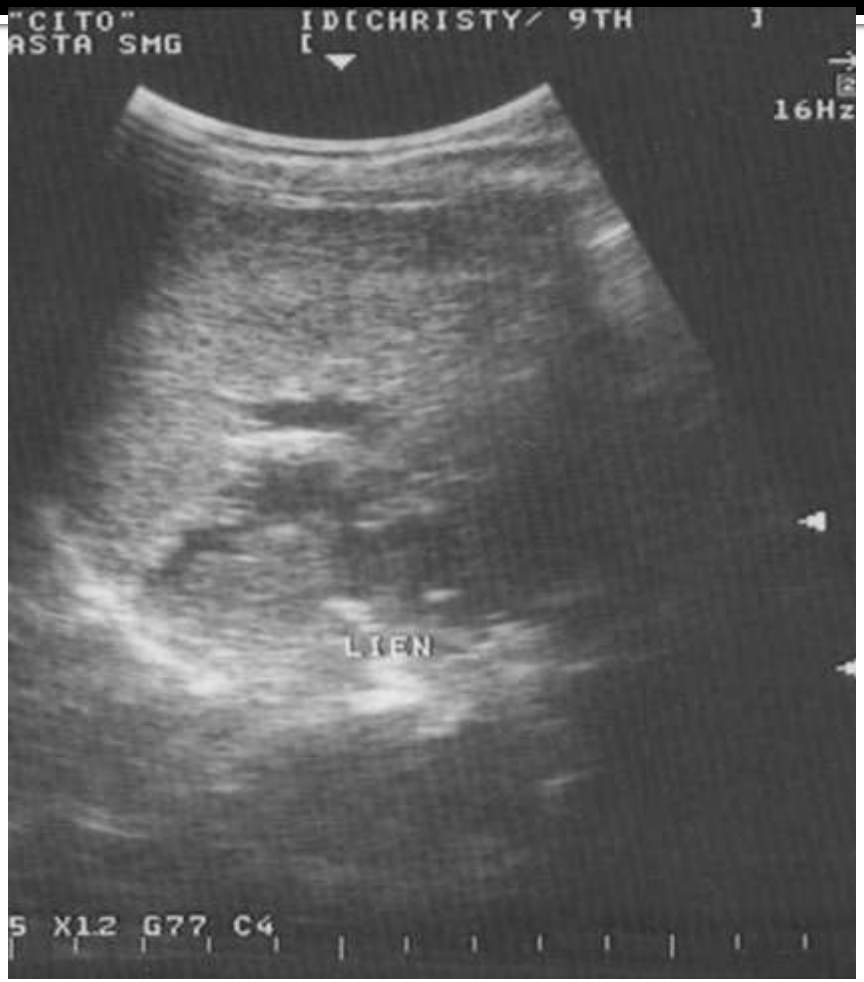

Lien Normal

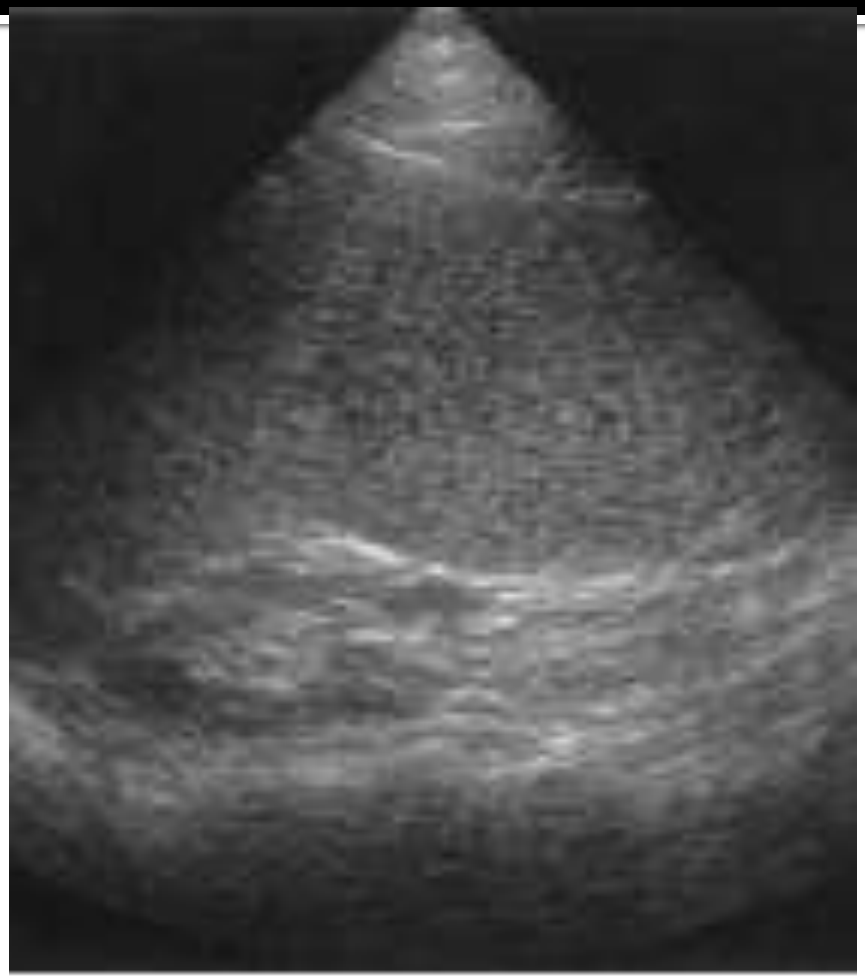

Splenomegali

Ultrasonografi Vesica Felea

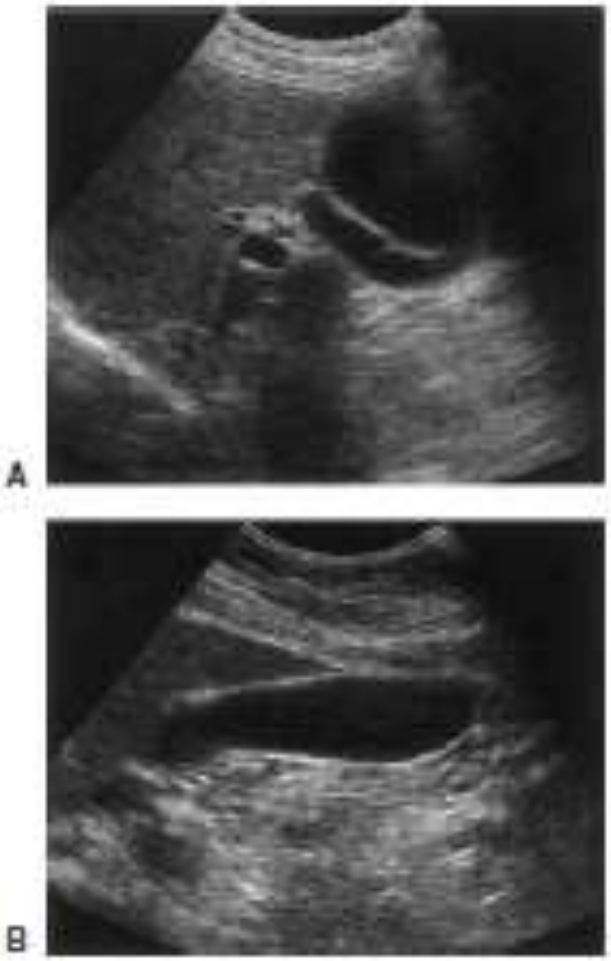

Vesica Felea Normal

Ultrasonografi Vesica Felea

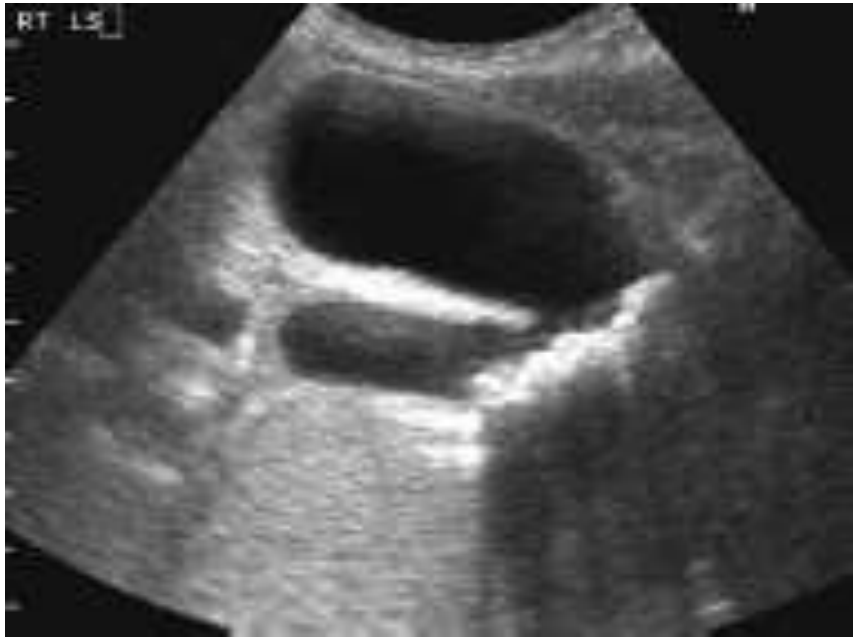

Cholesistolithiasis

Ultrasonografi Pankreas

A

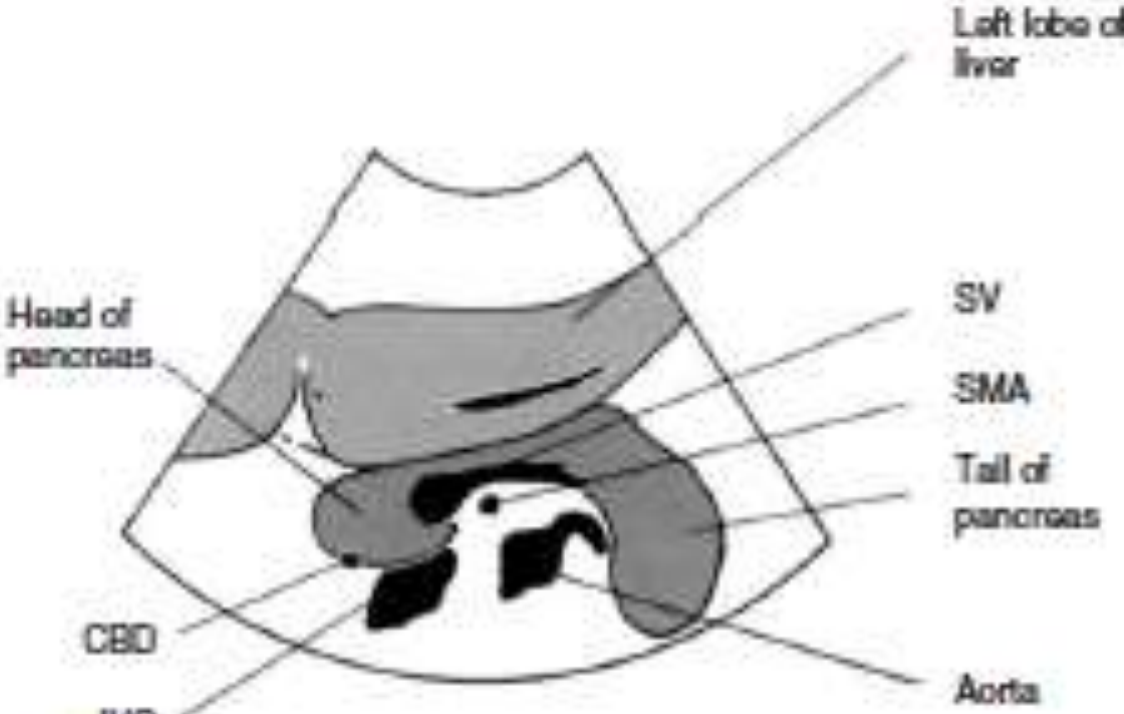

B

Ultrasonografi Pankreas (kalsifikasi)

Ultrasonografi (Pankreatitis)

CT Scan (Computed Tomography)

- Merupakan teknik pencitraan yang menggunakan kombinasi X-Ray dengan Computer untuk menghasilkan gambaran cross sectional dari suatu organ
- Pada kasus Gastrointestinal menggunakan kontras peroral dan intravena
- Pada kasus massa hepar dilakukan dynamic contrast (4 fase)
- Syarat : kadar creatinin darah harus < 2 mg/dl
- Kontraindikasi : pasien yang alergi kontras

CT Scan (Computed Tomography)

CT Scan 4 fase (dynamic contrast) :

- Early arterial (18-25 detik)
  - Indikasi: Paling baik memerlihatkan angiografi dari arteri hepatika
- Late arterial (35-40 detik)
  - Indikasi: Untuk mendeteksi dan melihat karakteristik dan tumor yang hipervaskular
- Portal venous (parenchymal) (70 detik)
  - Indikasi: Selalu dilakukan pada semua pemeriksaan CT Scan
- Equilibrium (delayed) (2-10 menit)
  - Indikasi: Sebagai tambahan untuk melihat karakteristik atau kecurigaan pada tumor hepar
  - Terutama pada kasus hemangioma atau cholangiocarcinoma

CT Scan Hepar

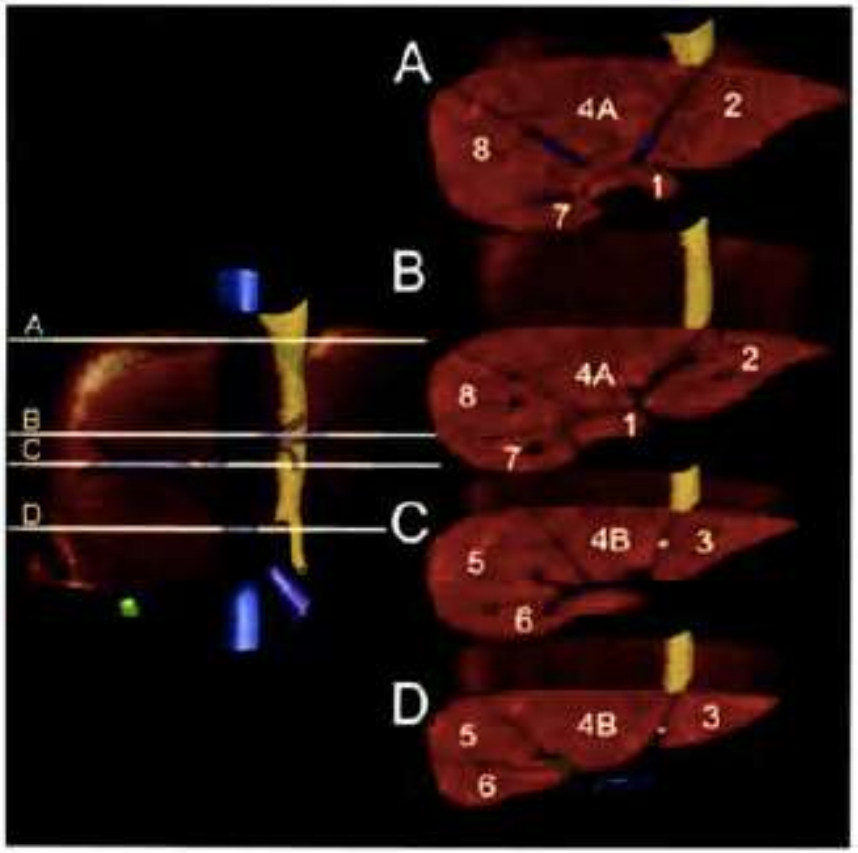

Graphic shows 4 sections through the liver depicting the 8 segments of the liver which are separated by vertical planes through the hepatic veins & horizontal plane through the portal vein.

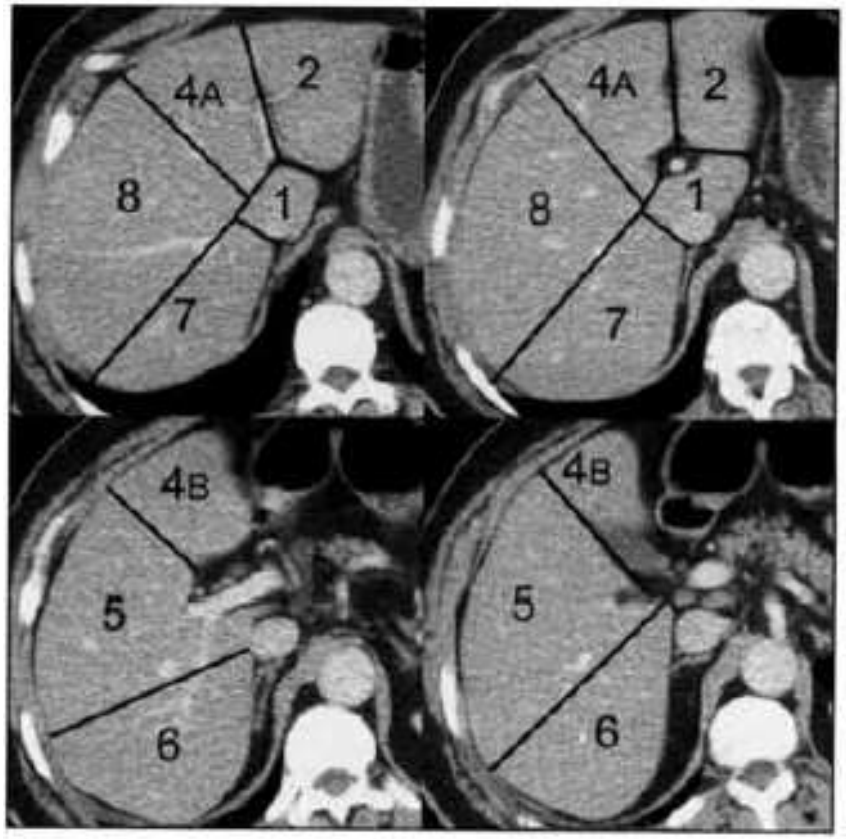

Axial CECT sections correspond to levels in graphic. Liver segments are numbered. Falciform ligament plane separates medial (seg. 4) from lateral (segs. 2 &3) left lobe. Seg. 3 not shown.

Sirosis Hepatis

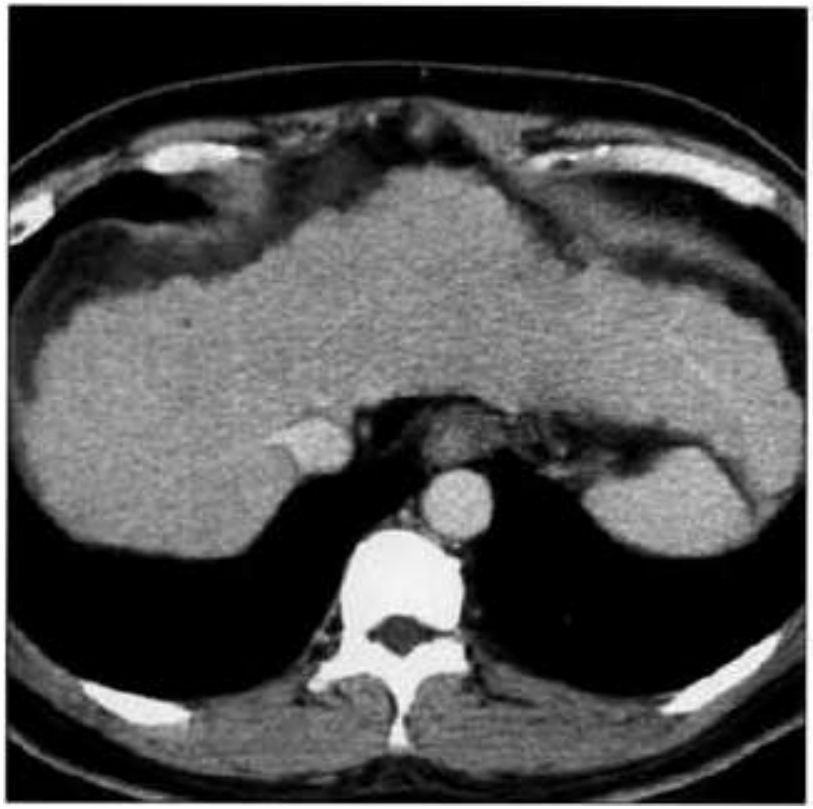

Hepar ukuran mengecil dengan tepi yang ireguler

HEPATOCELULAR CARCINOMA

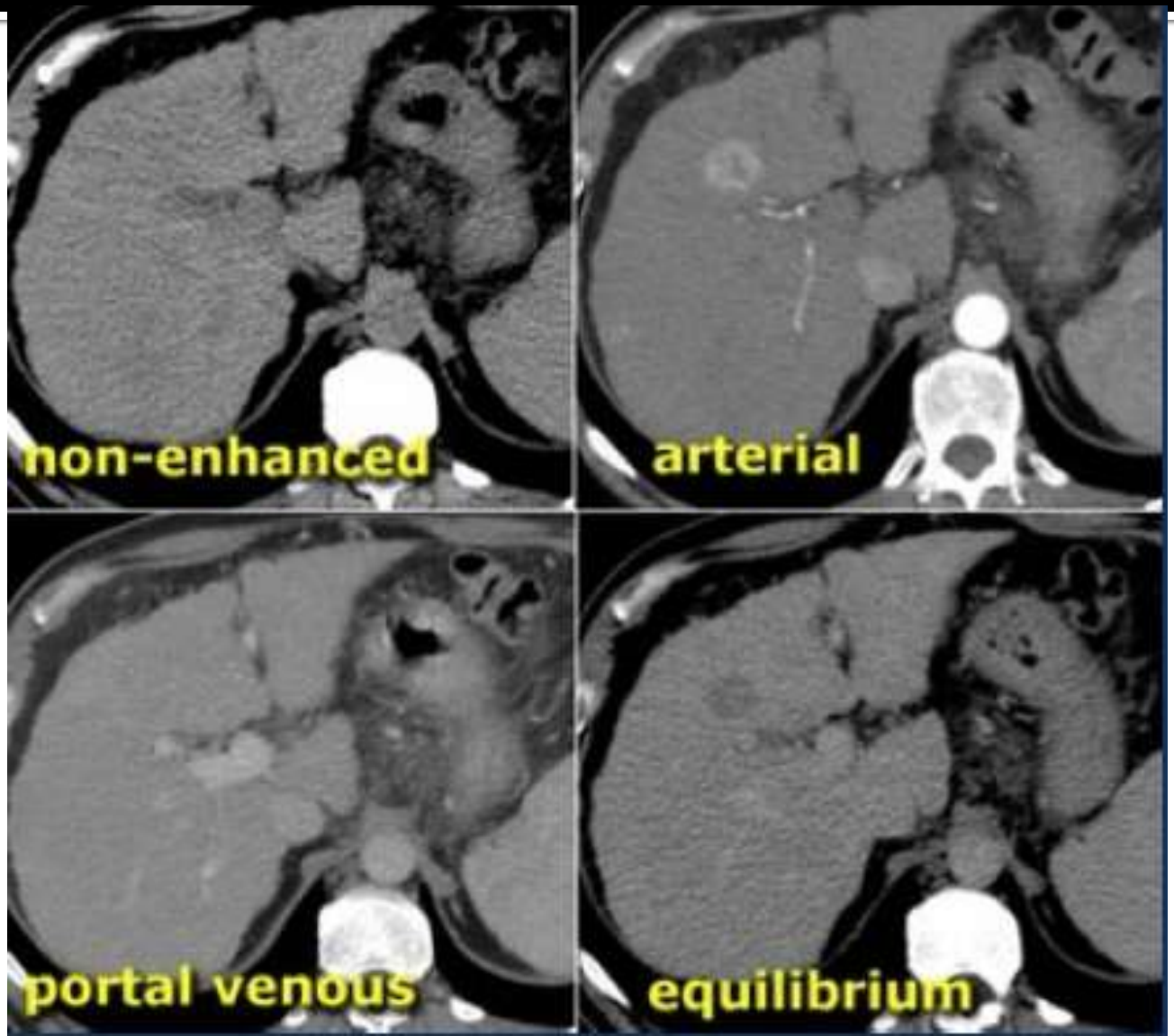

Abses Hepar

Lesi kistik bersepta pada hepar

BEBERAPA CONTOH KASUS

Multimodalitas Imaging

Cholesistitis

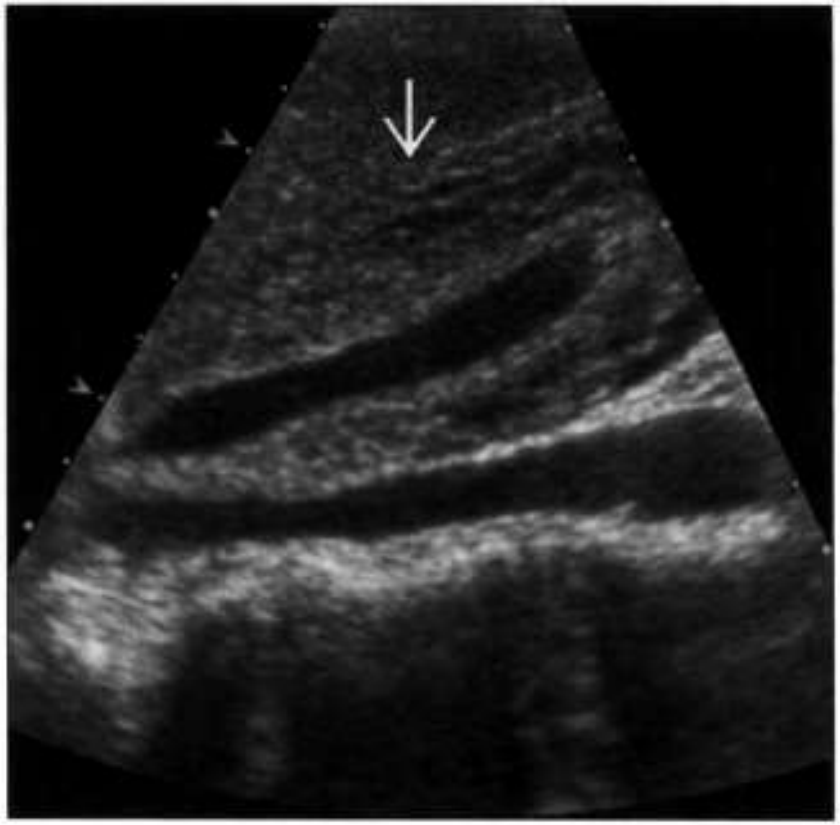

CHOLESISTITIS

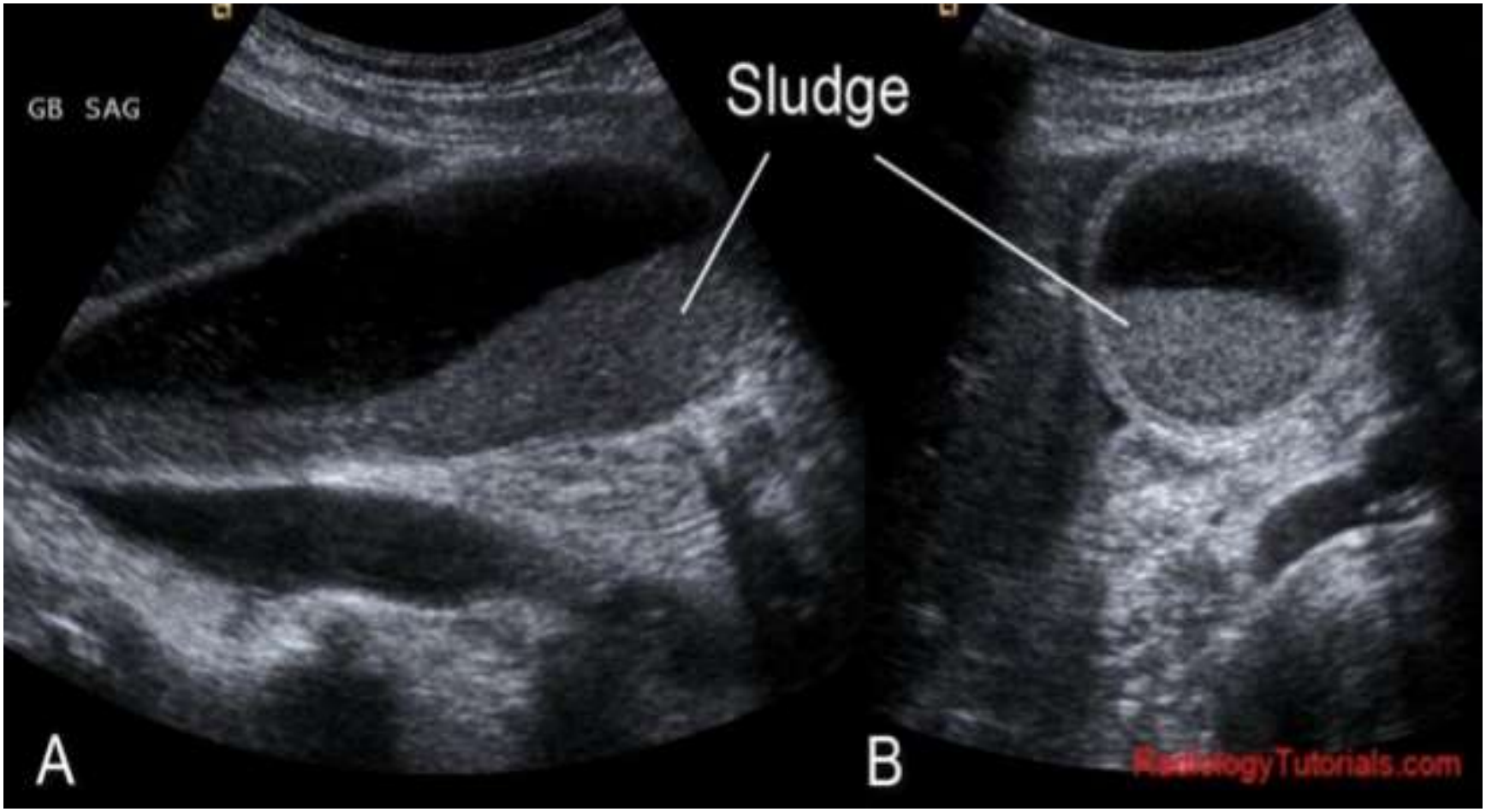

CHOLELITHIASIS

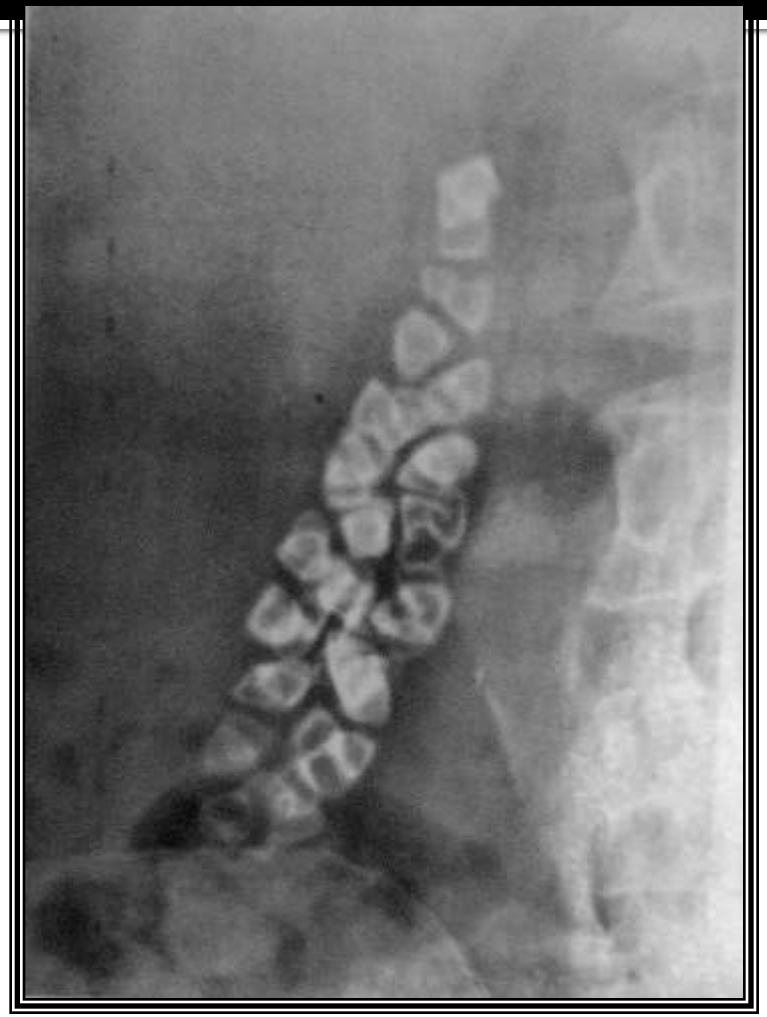

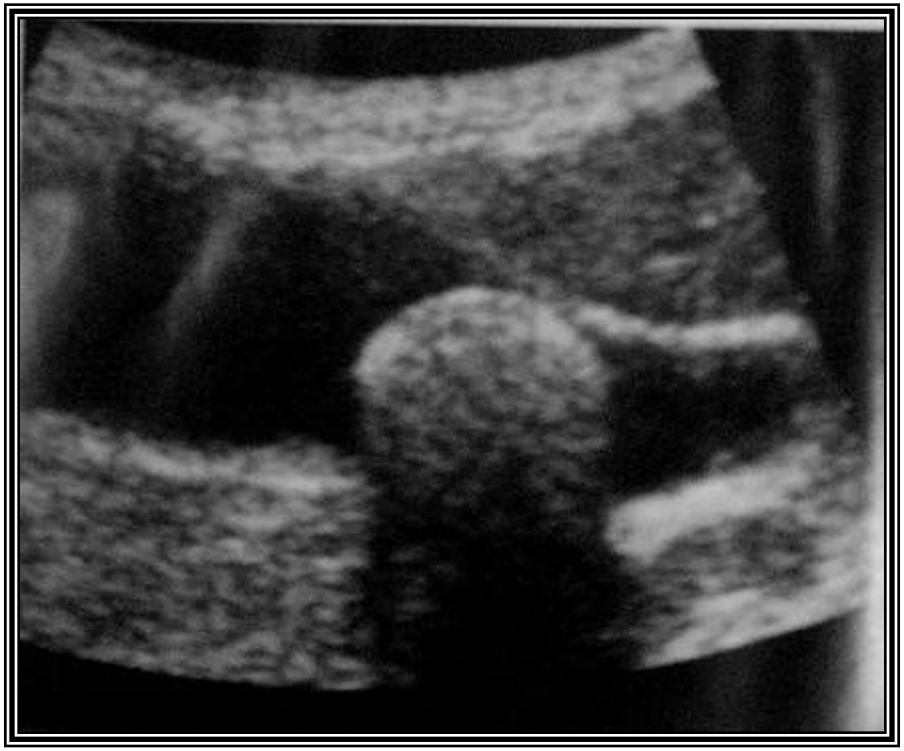

INTUSUSEPSI

INTUSUSEPSI

INVAGINASI / INTUSSUSEPSI

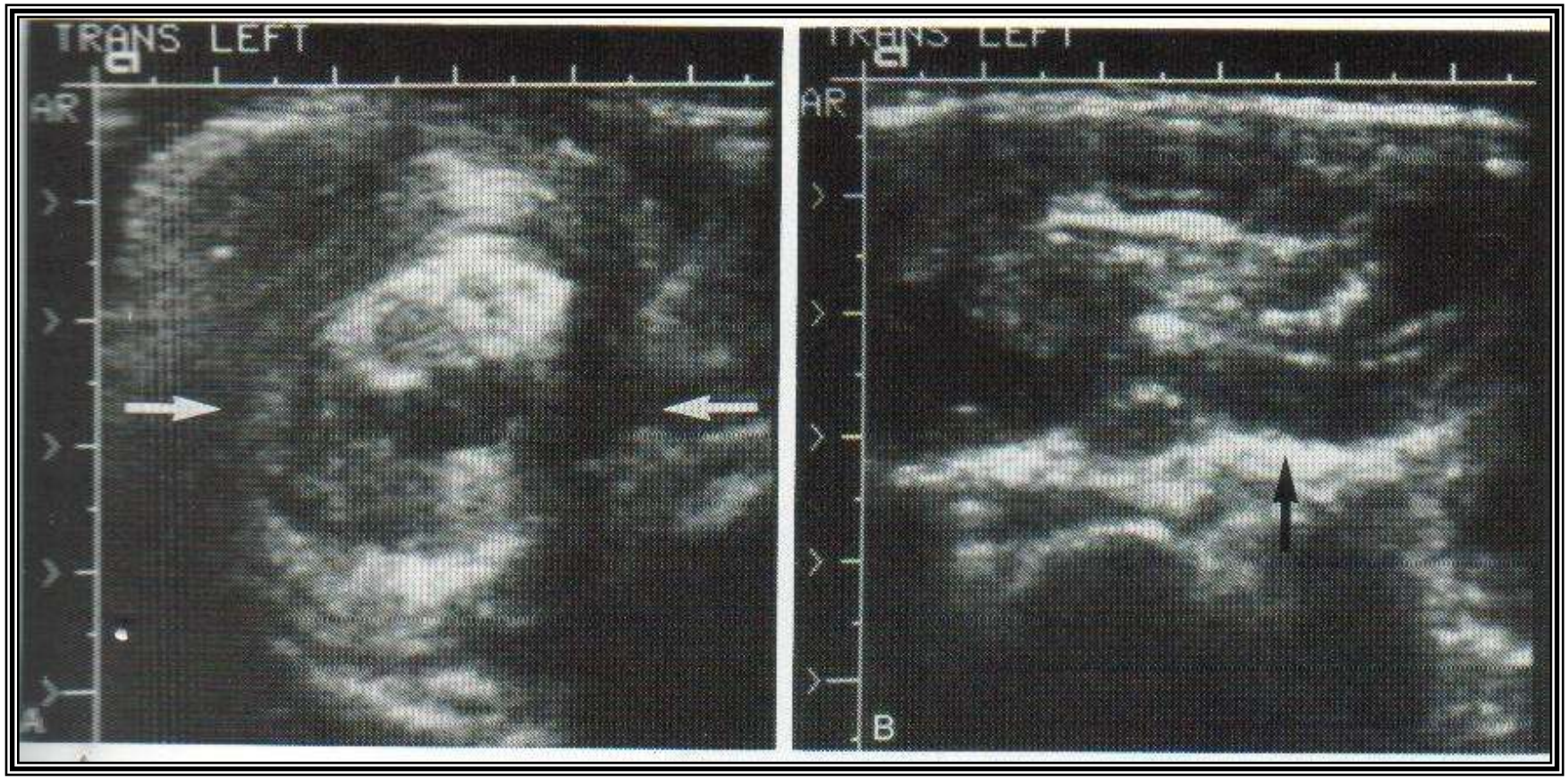

INTUSUSEPSI

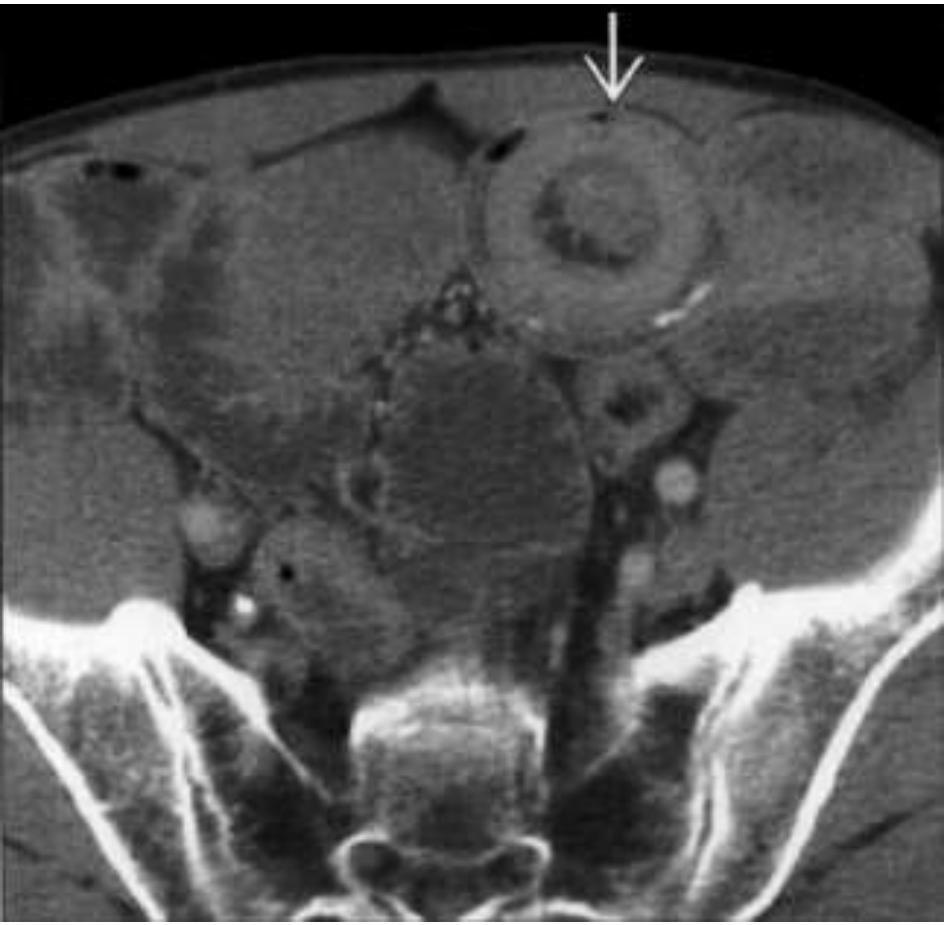

Appendicitis

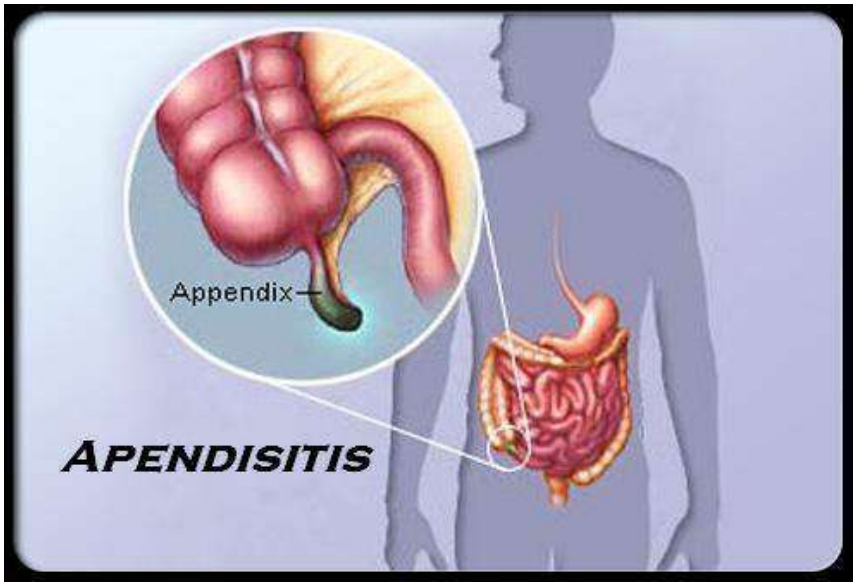

Appendicitis

Appendicitis

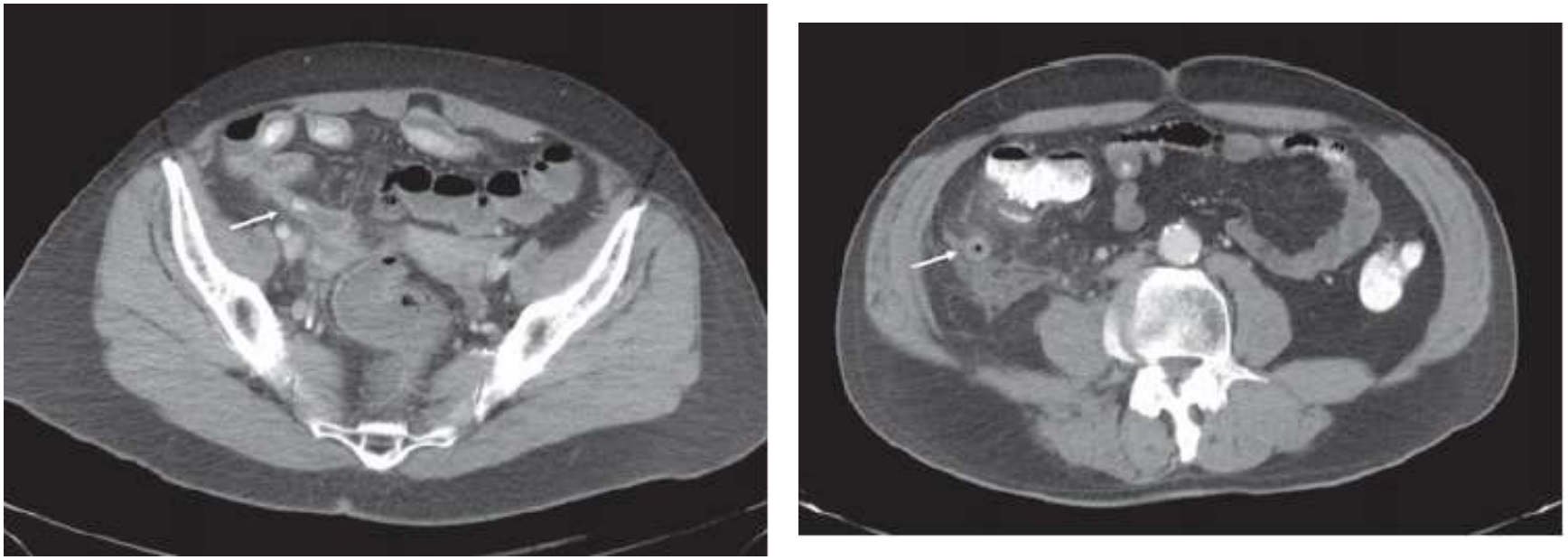

Figure 3.2 Appendicitis. Computed tomographic findings of acute appendicitis. Oral and i.v. contrast-enhanced computed tomography scan shows a thickened, fluid-filled appendix with an appendicolith (arrow) visualized within the lumen **(a)**. Cross-sectional image of a thickened, inflamed appendix with adjacent periappendiceal fat stranding **(b)**.

TERIMA KASIH