PENGANTAR PEMERIKSAAN FISIK PARU

LUSITO
Bagian penyakit dalam FK/RS Sultan Agung
Semarang

2015

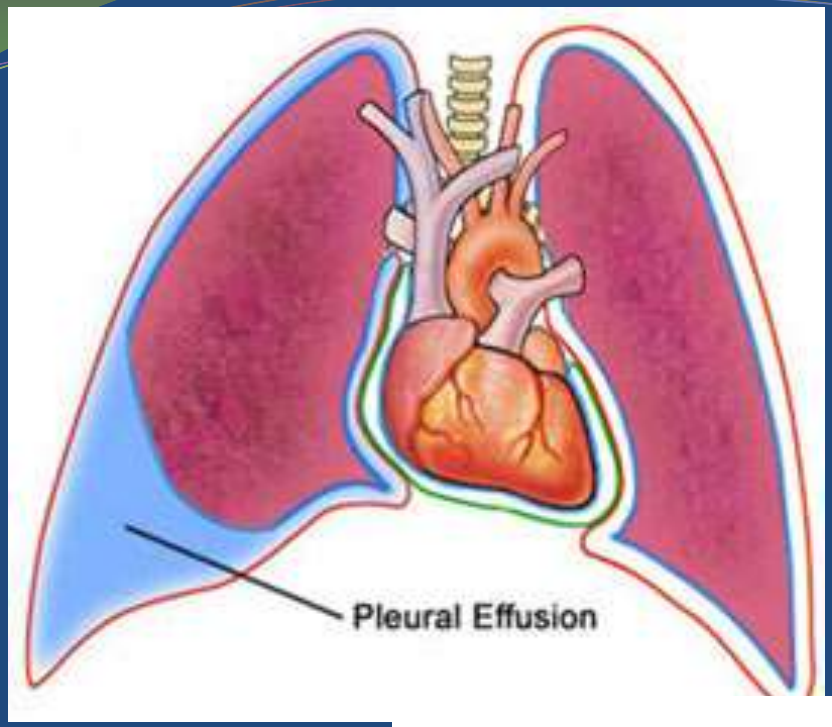
Pleural Effusion

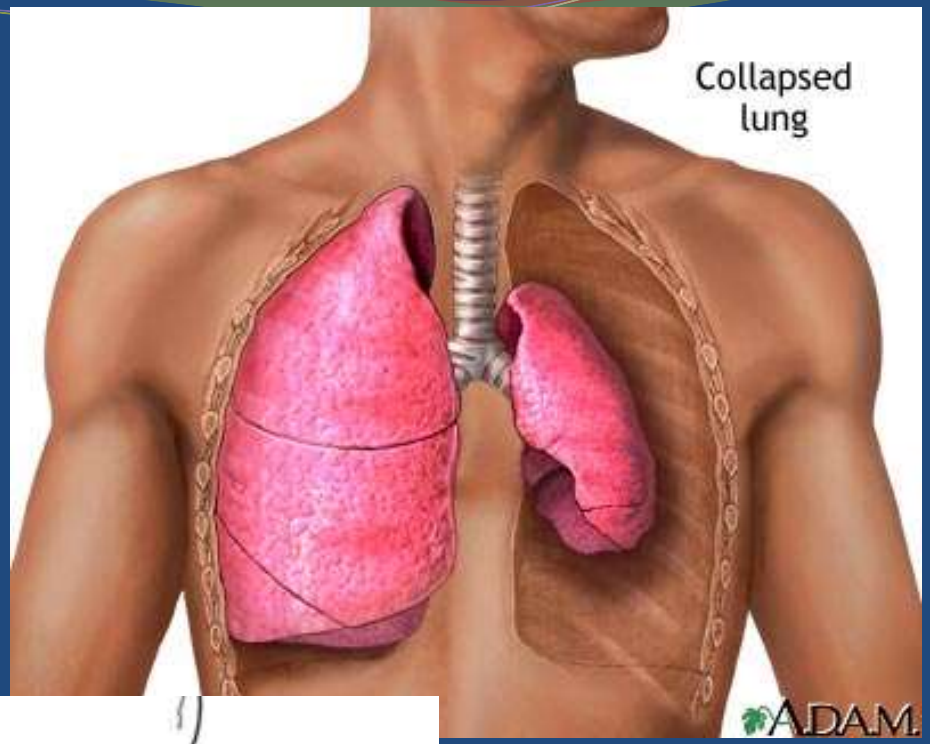
Collapsed lung
A.D.A.M.

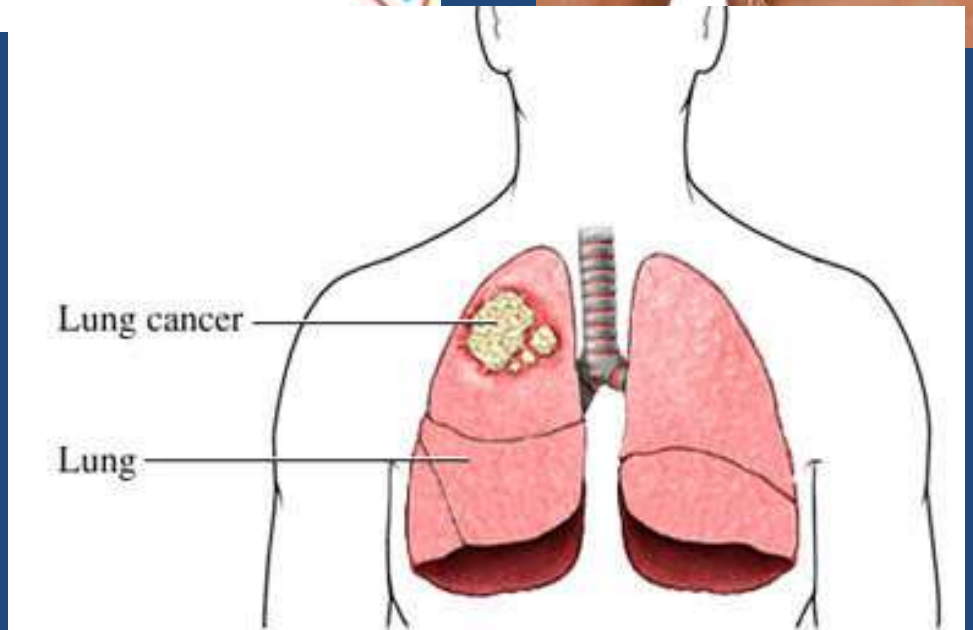
Lung cancer
Lung

THORAKS

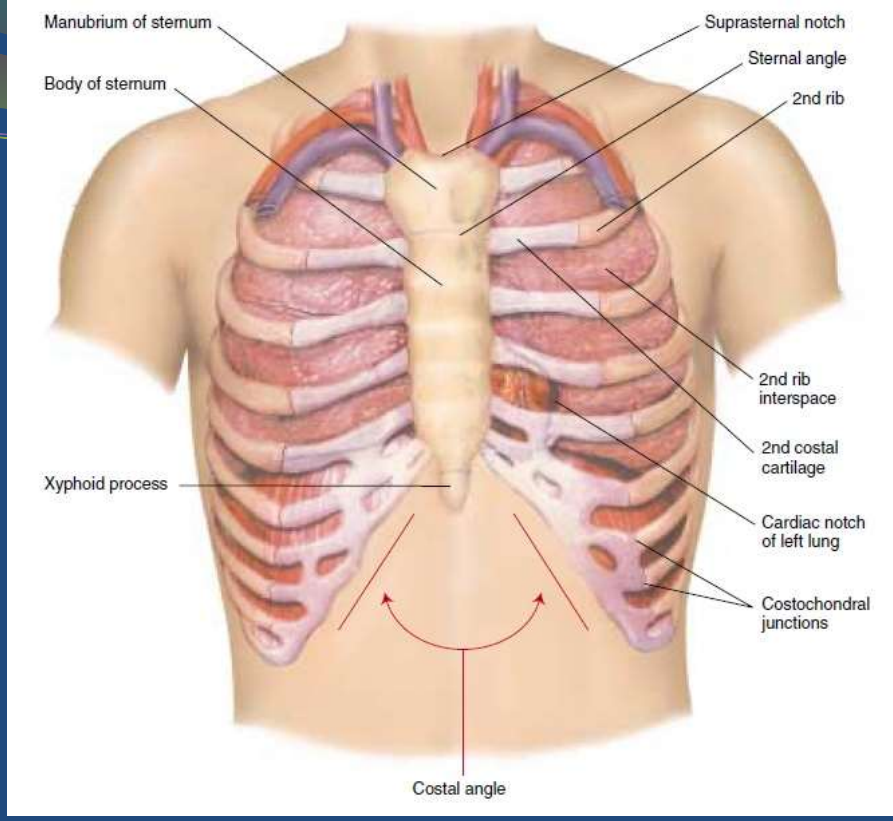

1. Dinding thoraks
2. Pleura
3. Rongga pleura
4. Saluran nafas
5. Jaringan paru

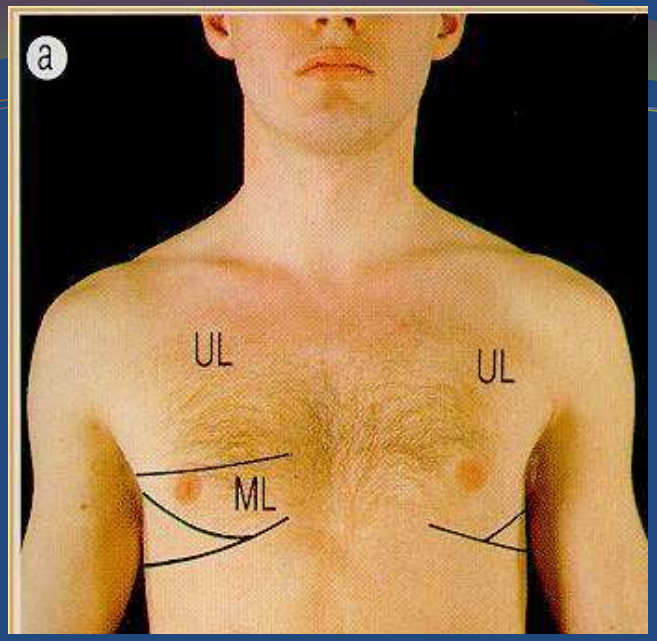

1. Dinding thoraks

- kulit, subkutis, otot, tulang, pembuluh darah, syaraf
- Penghalang bising/suara paru
- Sumber bising : krepitasi subkutis

Pleura parietalis

Pleura viseralis

2. Pleura

- Normal tidak mempengaruhi pemeriksaan fisik
- Schwarte/penebalan : menghambat pengembangan paru, penghalang bising/suara paru
- Sumber bising : bising gesek pleura

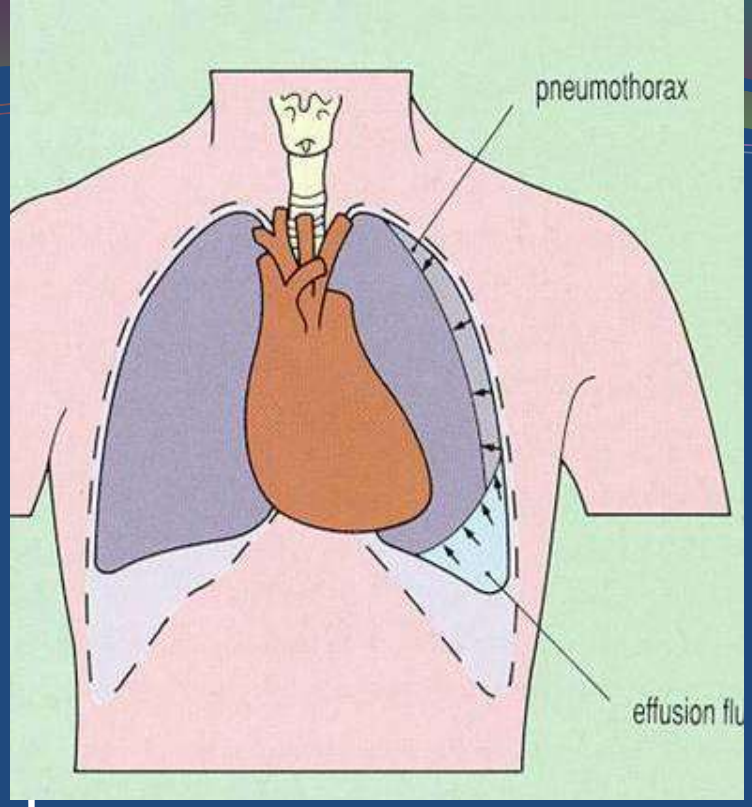

3. Rongga pleura

- Normal tidak mempengaruhi pemeriksaan fisik
- Penghalang bising : bila terisi cairan, udara, jaringan padat
- Sumber bising : succussio hipokrates

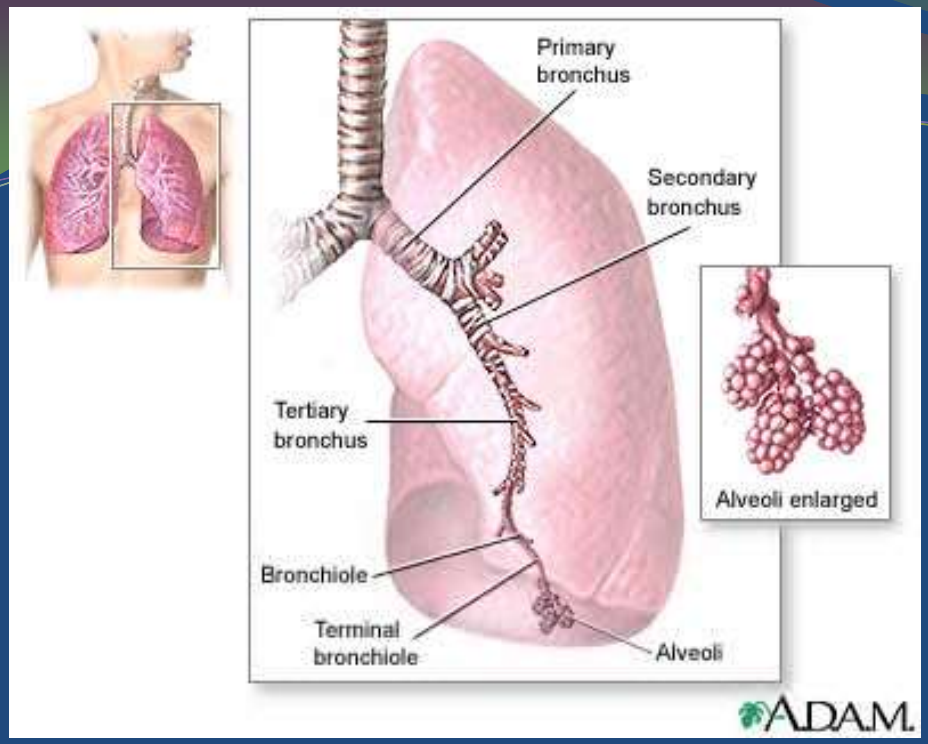

4. Saluaran pernafasan

- Trakhea-bronkiolus terminalis
- Sumber bising :
    - bising trachea, bising broncial
    - Wheezing, Ronkhus , Amforik

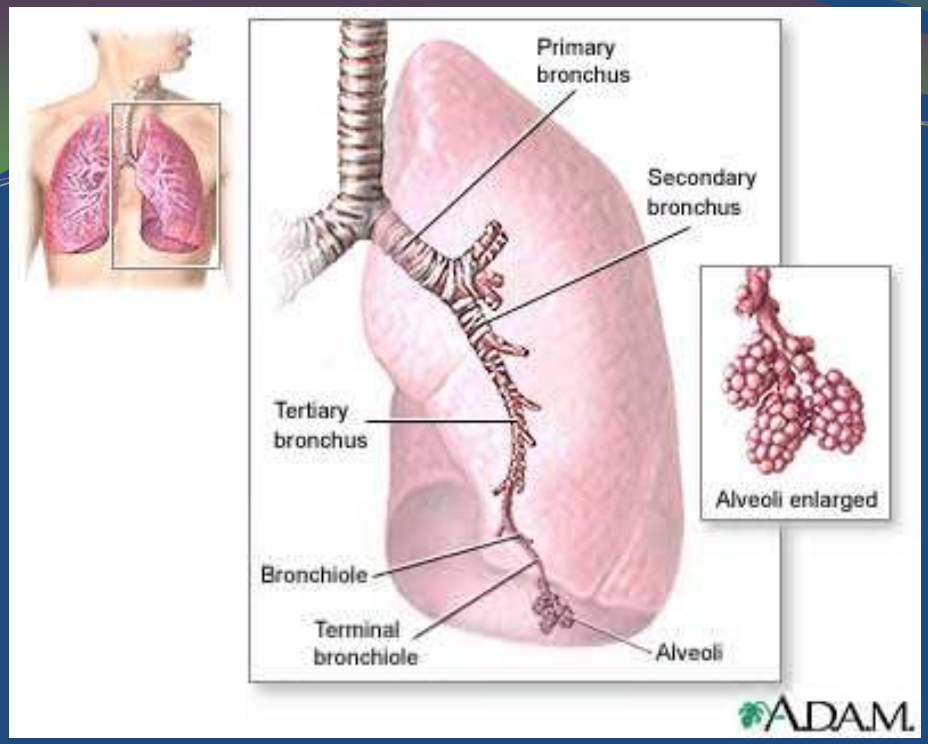

5. Jaringan paru

- Bronchiolus respiratorius- alveolaris
- Sumber bising :
    - bising vesiculer, (suara dasar/pokok)
    - krepitasi, ronkhus halus
- Penghalang bising

PF Paru berdasar pada

1. Pengembangan alveoli
2. Udara didalam alat pernafasan
3. Arus udara
4. Saluran udara
5. Penghalang

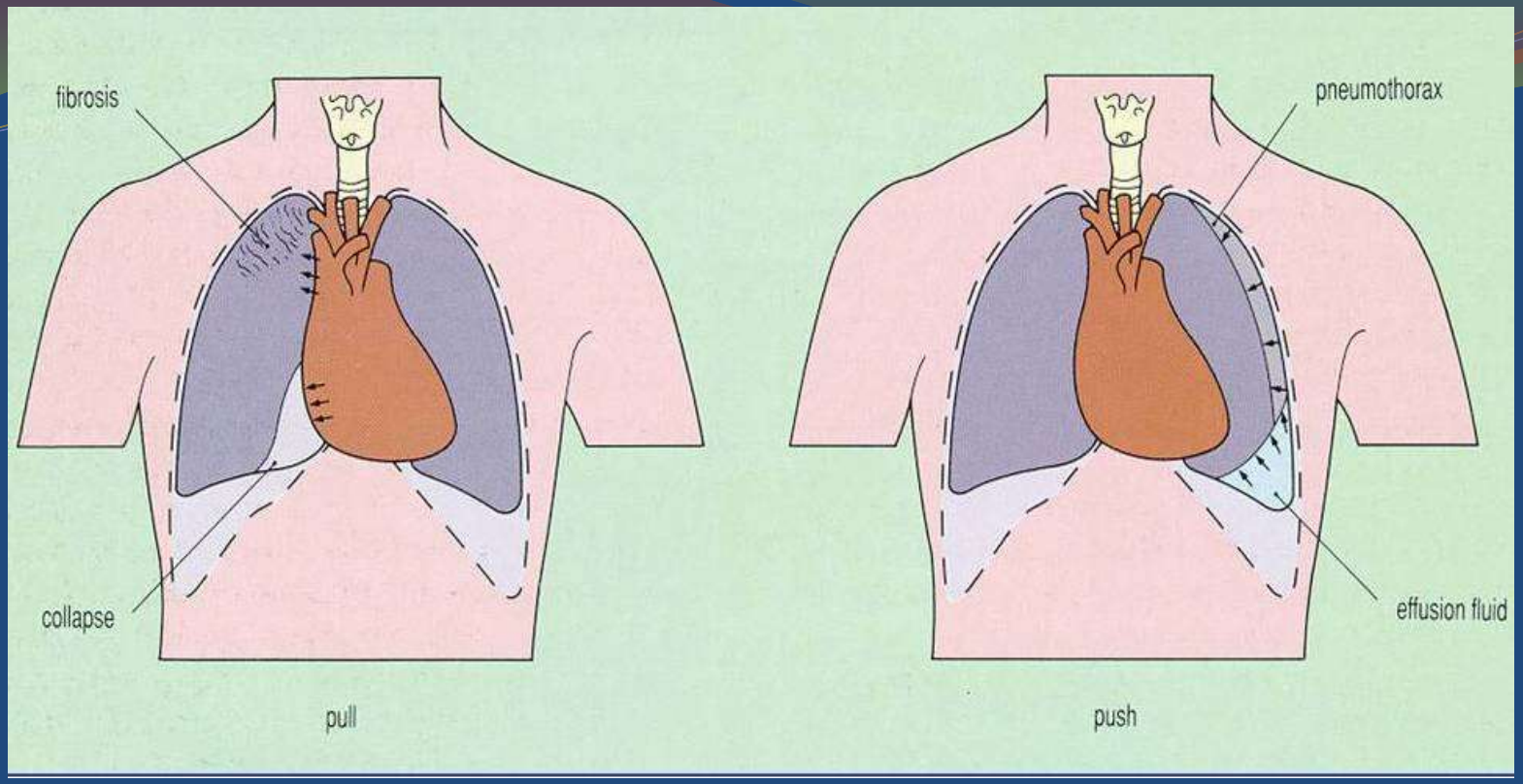

Pengembangan Paru

Inspeksi: - Simetris

- Asimetris
- Gerakan dinding dada tertinggal

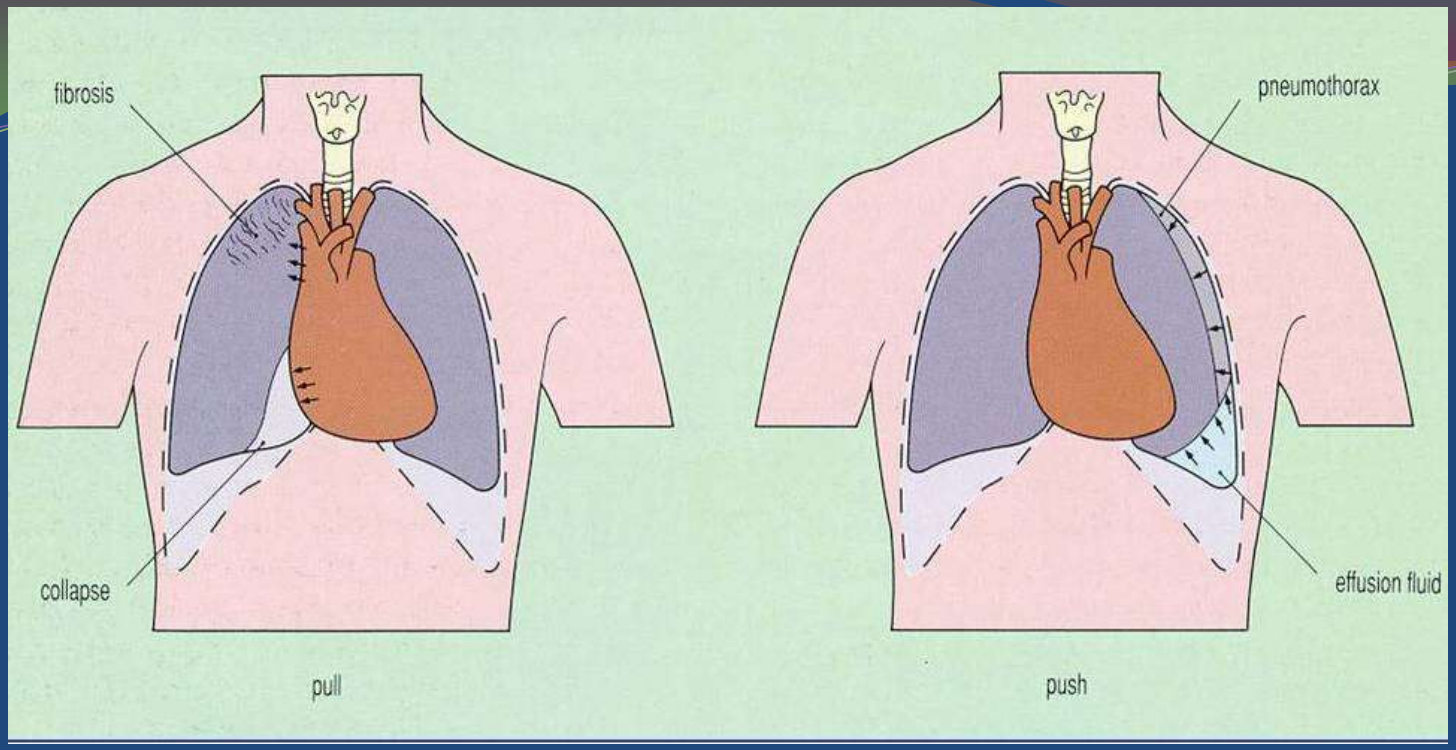

Penghalang

Palpasi : - Fremitus normal

- Fremitus mengeras

- Fremitus melemah

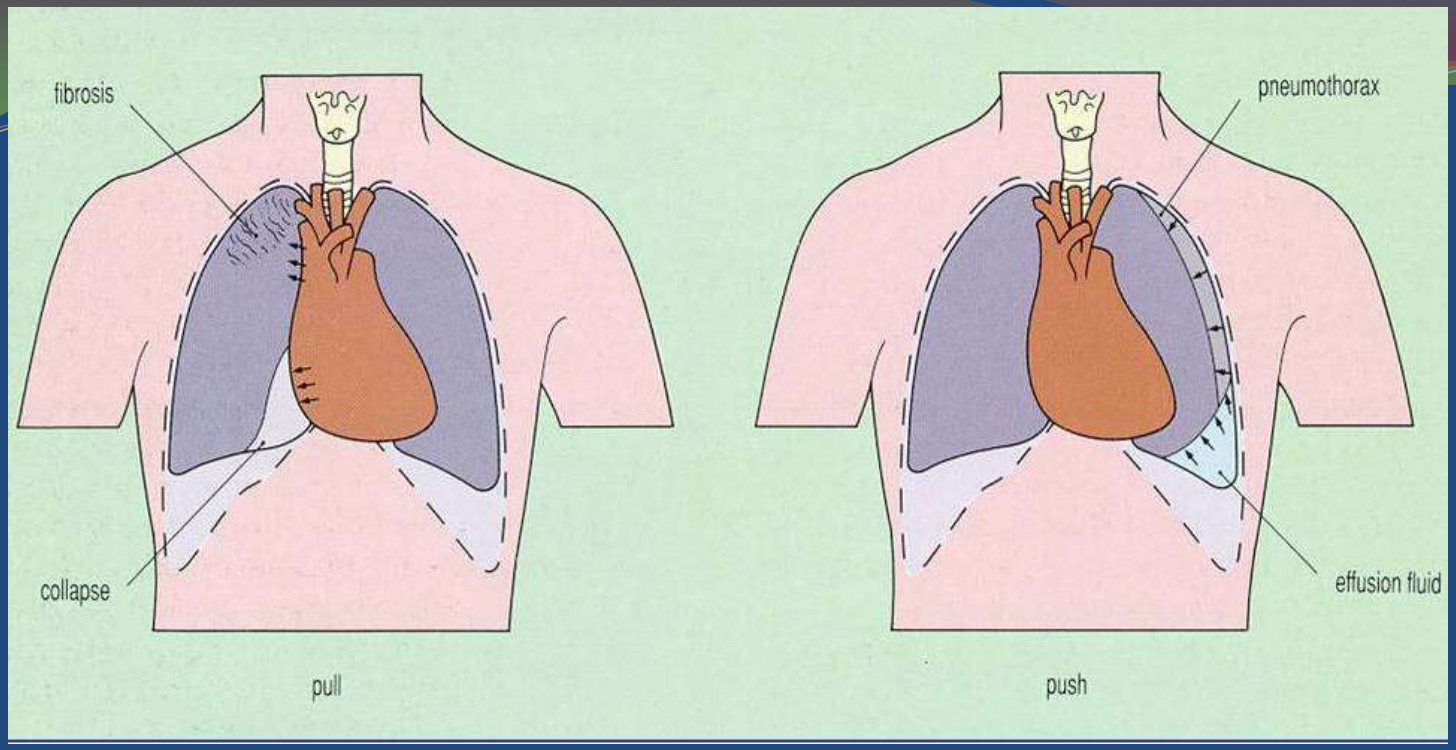

Udara didalam alat pernafasan

Perkusi : - bising ketok sonor
- bising ketok hipersosnor
- bising ketok redup
- bising ketok pekak

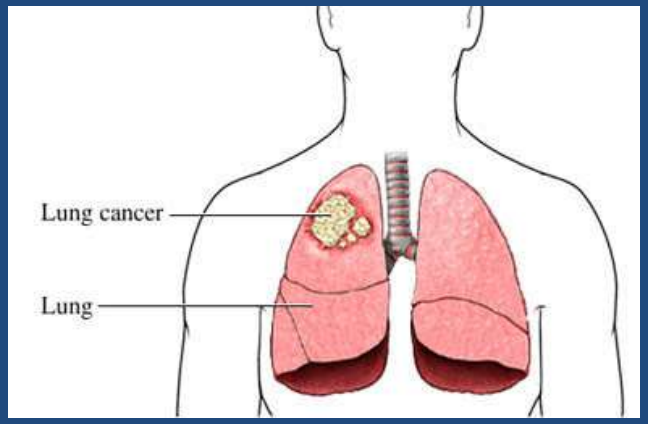

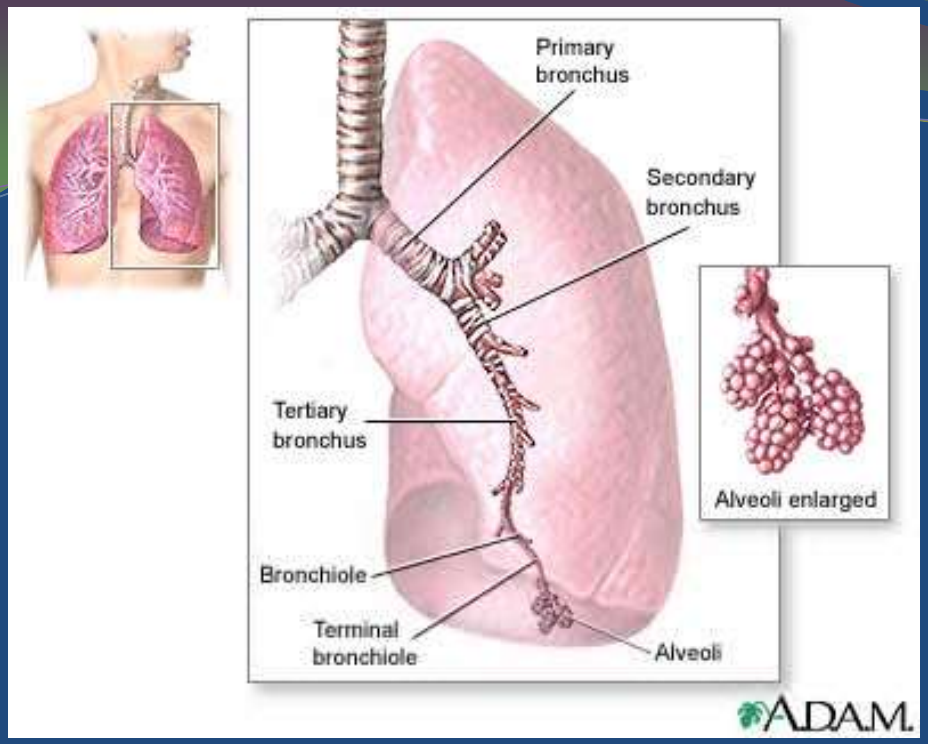

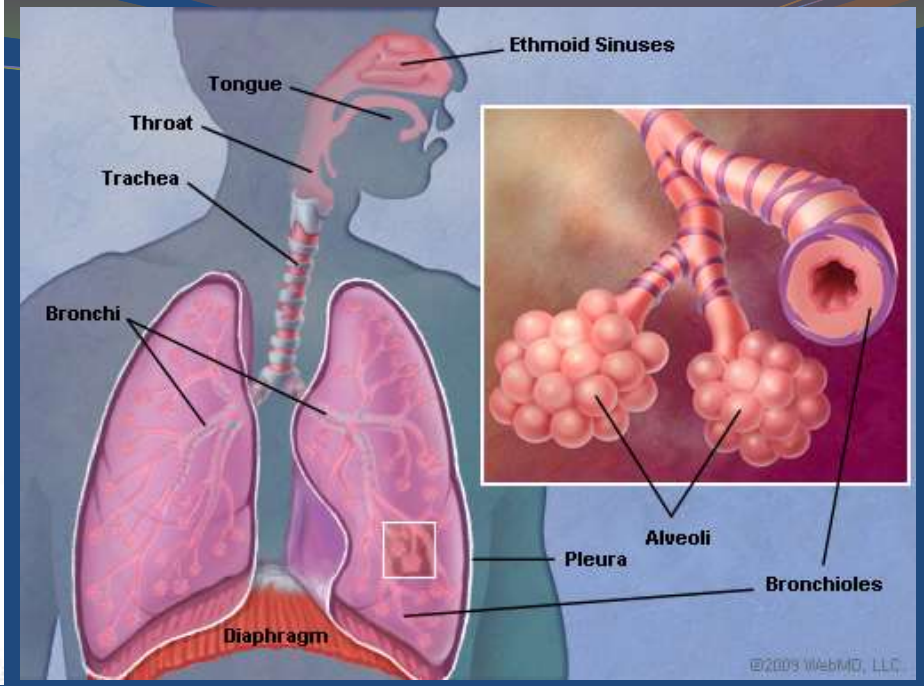

Arus udara

Auskultasi : - bising tracheal

- bising bronchial

-bising vesikuler

Characteristics of Breath Sounds

	Duration of Sounds	Intensity of Expiratory Sound	Pitch of Expiratory Sound	Locations Where Heard Normally
Vesicular*	Inspiratory sounds last longer than expiratory ones.	Soft	Relatively low	Over most of both lungs
Broncho-vesicular	Inspiratory and expiratory sounds are about equal.	Intermediate	Intermediate	Often in the 1st and 2nd interspaces anteriorly and between the scapulae
Bronchial	Expiratory sounds last longer than inspiratory ones.	Loud	Relatively high	Over the manubrium, if heard at all
Tracheal	Inspiratory and expiratory sounds are about equal.	Very loud	Relatively high	Over the trachea in the neck

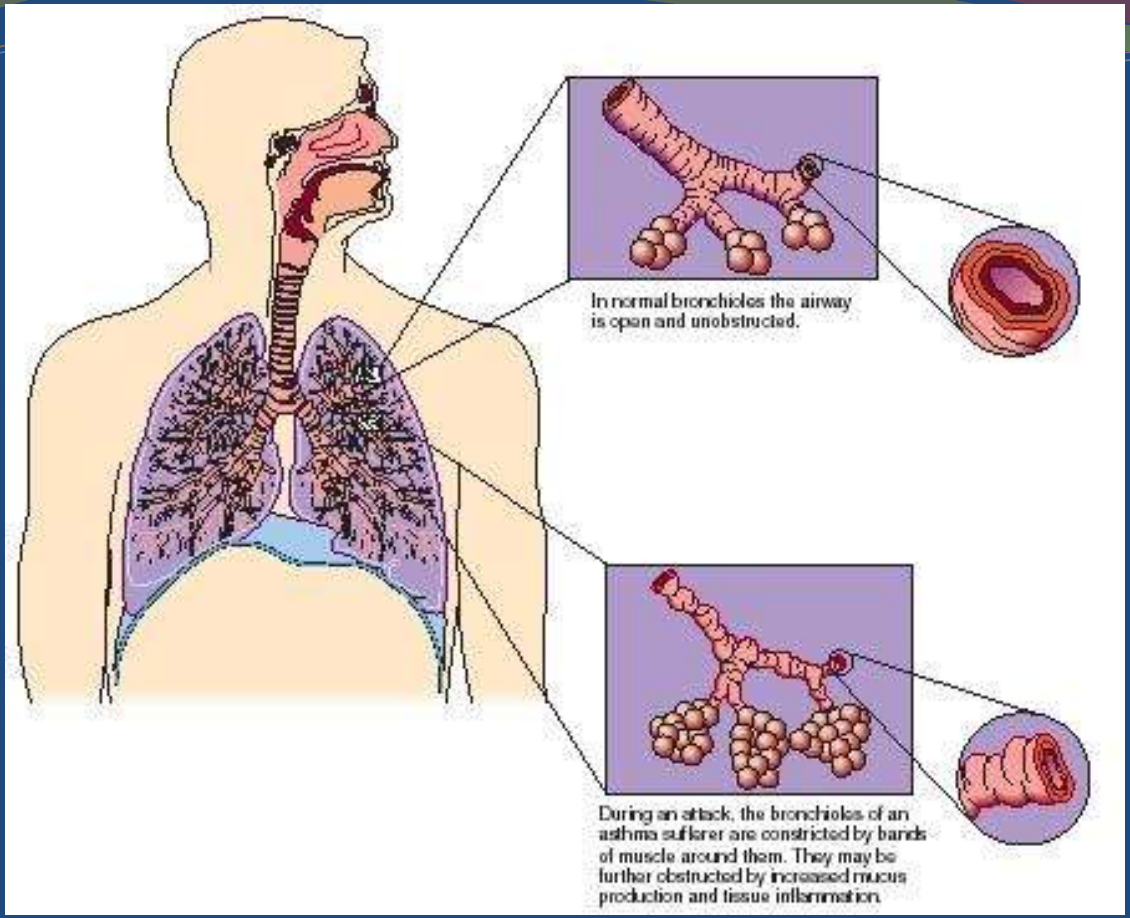

Saluran udara

- Penyempitan : - bising diperkeras
  - wheezing

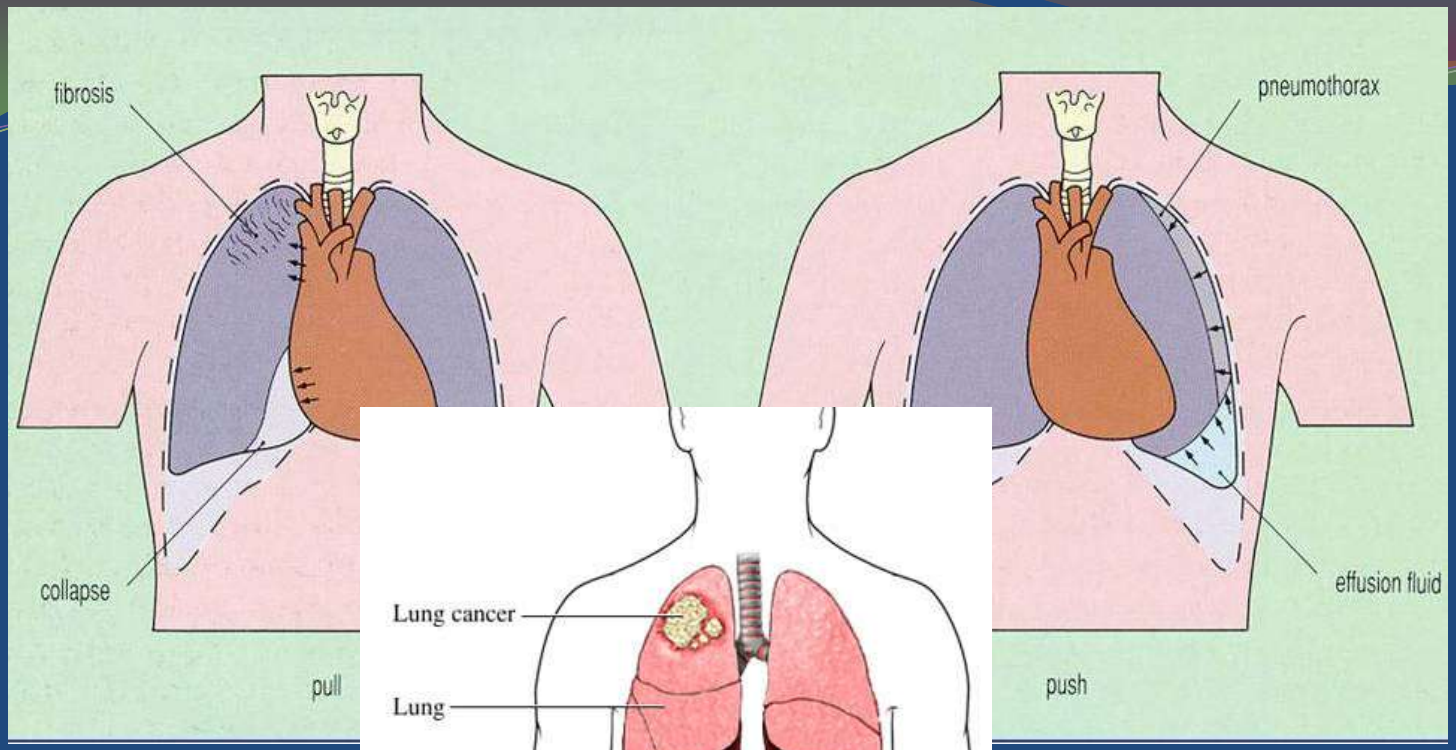

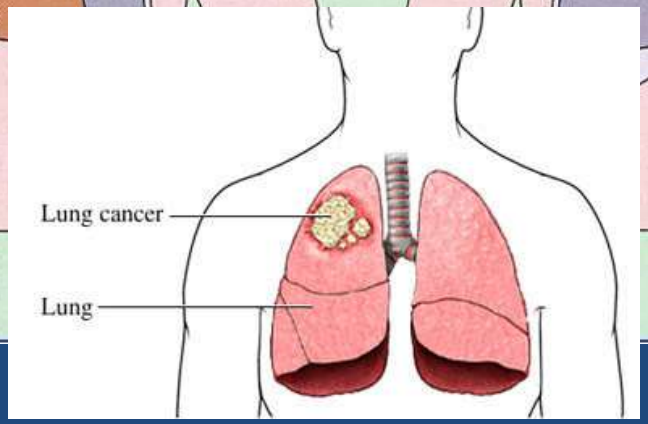

Penghalang

Auskultasi : - Suara nafas menurun

- Suara nafas menghilang

Infiltrat paru/konsolidasi

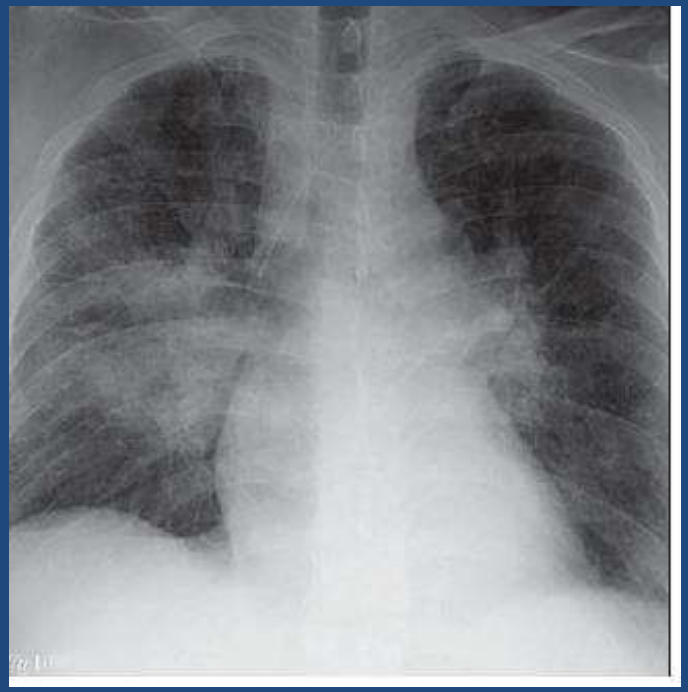

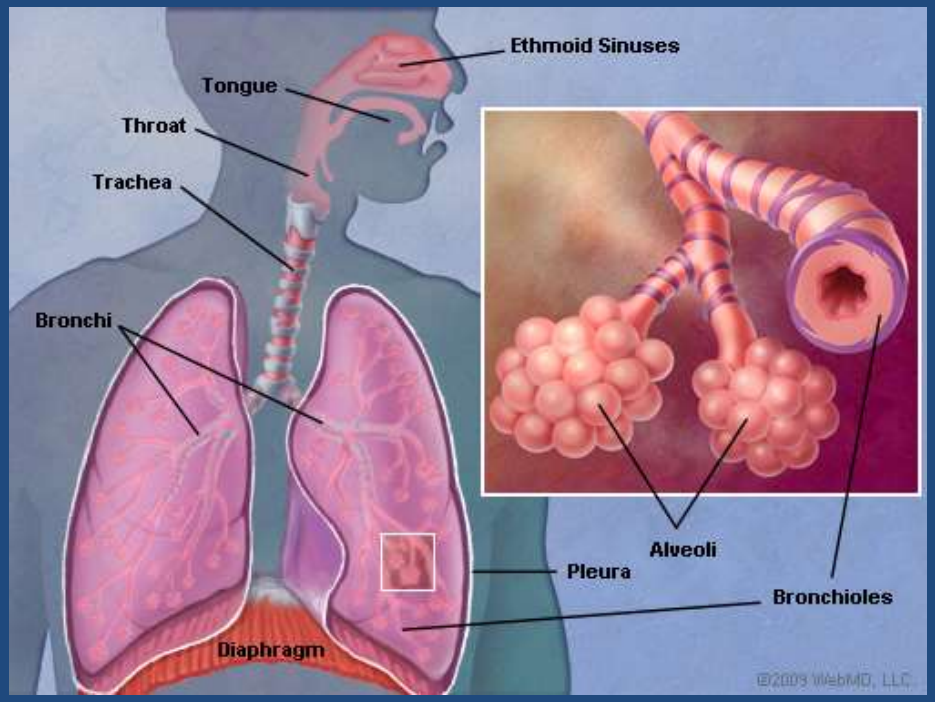

Infiltrat paru media penghantar suara yang baik

Auskultasi : - Suara nafas mengeras
- Suara nafas bronkial
- Ronki basah

Pemeriksaan fisik pada kelainan paru

Kelainan	Inspeksi	Palpasi	Perkusi	Auskultasi
Asma br./ Emfisema	Simetris Hprinflasi Ics >	Ekspansi↓ Fremitus↓	Hprsonor Dfrgma ↓	Wheezing (+) Ekspirasi pjg
Konsoli-dasi	Btk tetap Grk nps ↓	Grk nps ↓ Fremitus↑	Redup	Bronkial Ronki (+) Brfoni (+)
Efusi pleura	Asimetris Grk nps ↓ Ics >	Pendo-rongan Grk nps ↓ Fremitus↓	Redup	Suara nps ↓ sp tdk terde-ngar

Pemeriksaan fisik pada kelainan paru

Kelainan	Inspeksi	Palpasi	Perkusi	Auskultasi
Pneumo-toraks	Asimetris Grk nps ↓ Ics >	Pendo-rongan Grk nps ↓ Fremitus↓	Hprsonor	Suara nps ↓ sp tdk terde-ngar
Atelek-tasis	Asimetris Grk nps ↓	Penarikan Grk nps ↓ Fremitus↓	Redup	Suara nps ↓ sp tdk terde-ngar
Fibrosis	Asimetris Grk nps ↓ Ics <	Penarikan Grk nps ↓ Fremitus↑	Redup	Suara nps ↓ Ronki (+)