

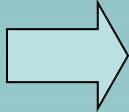
# PENGELOLAAN RETENSIO URINE



---

**Vito Mahendra Ekasaputra**  
**Bag.Bedah**  
**FK UNISSULA/RSI Sultan Agung**  
**Semarang**

- Definisi :

 urine terkumpul dalam buli dan tidak dapat keluar sempurna.

Pembagian :

- R.U Partial : - miksi (+)
  - Rest urine (+)
- R.U Total : - miksi (-)
  - buli penuh

- Diagnosis Buli Penuh
  1. Supra pubik cembung
  2. Palpasi : - lunak
    - fluktuasi (+)
    - nyeri tekan (+)
  3. Perkusi : pekak (+)
  4. Kateterisasi → urine (+)
  5. Pungsi supra pubik (+)
  6. U S G
  7. Foto kontras

- Retensi Urine Akut

1. Obstruksi mekanik

- batu uretra
- tumor buli
- bekuan darah
- uretrosistitis akut
- ruptur uretra

2. Neurogenik ( kerusakan saraf )

- trauma medulla spinalis
- dementia

- Retensio Urine Akut

3. Myogenic ( kerusakan otot detrusor )

- kontusio dinding buli
- operasi dinding buli
- ruptur dinding buli

4. Psikogenik

- stress psikis

- Retensio Urine Akut atau Kronis karena obat-obatan, misalnya :
  - a. Anti kolinergik
    - antihistamin non sedatif
    - propanthelin bromid
    - dicyclomin
    - ephedrin, dll
  - b. Non Narkotik Analgetik
    - golongan opiat

c. Anti depresan

- Imipramin HCl

d. Obat Hipertensi / Jantung

- beta blocker ( mis.propanolol )

- calcium channel blocker

  - (mis. dihydropyridone)

e. Cytostatica ( Vincristin )

- Retensio Urine Kronis

Akibat obstruksi mekanik, misalnya :

1. Anak – anak :
  - fimosis
  - parafimosis
  - posterior urethral valve
2. Dewasa :
  - meatal stenosis
  - striktur uretra
  - sklerosis leher buli
  - hamil / post partum



### 3. Orang Tua :

Wanita : - karunkula uretra  
- prolaps uteri

Laki – laki : - pembesaran prostat  
- tumor buli  
- striktur uretra

## Pengelolaan :

1. Pengosongan buli segera
  - a. kateterisasi
  - b. sistostomi
  
2. Terapi kausal

## Kateterisasi :

1. Desinfeksi

2. Pelumasan uretra

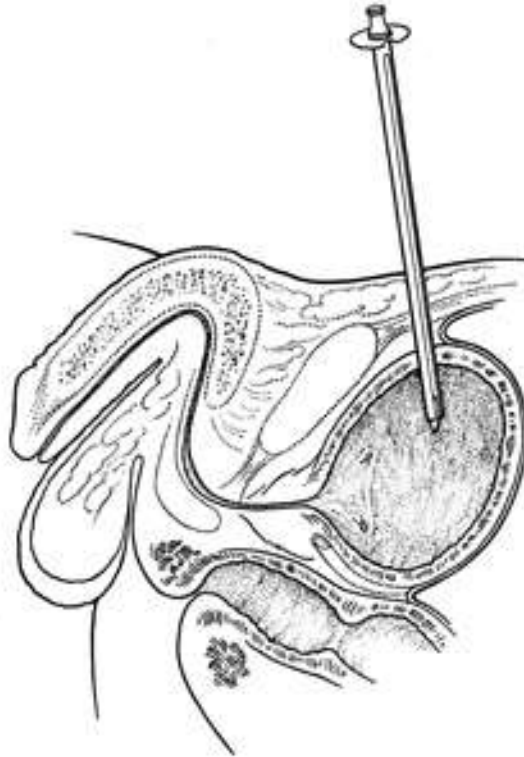
6 cc jelly / pelumas kateter + 4 cc lidocain




→ 3-5 menit dalam uretra

3. Pasang kateter ch14/16

# Cystostomy

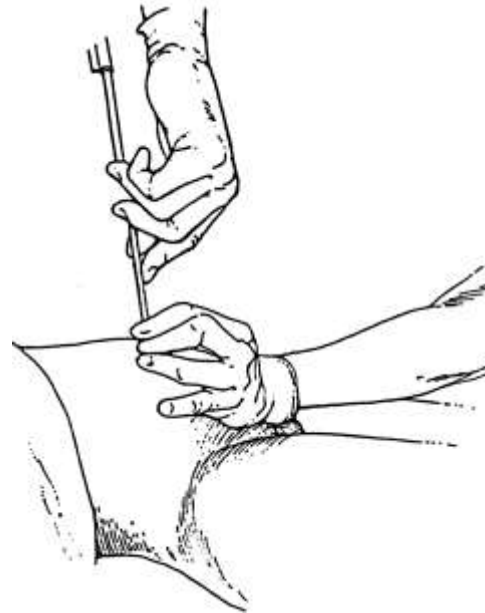
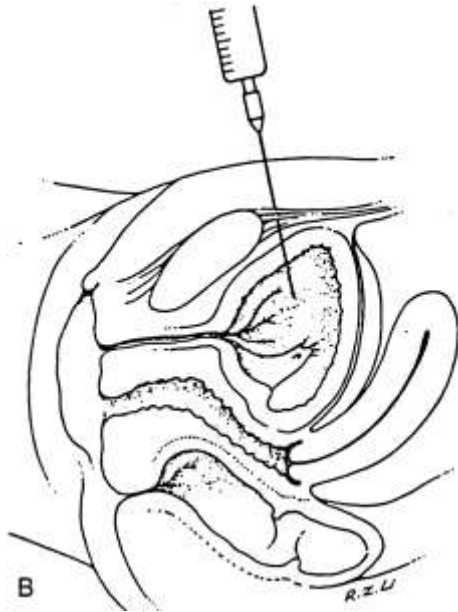
- Percutan cystostomy
  - Trocar + NGT No.10



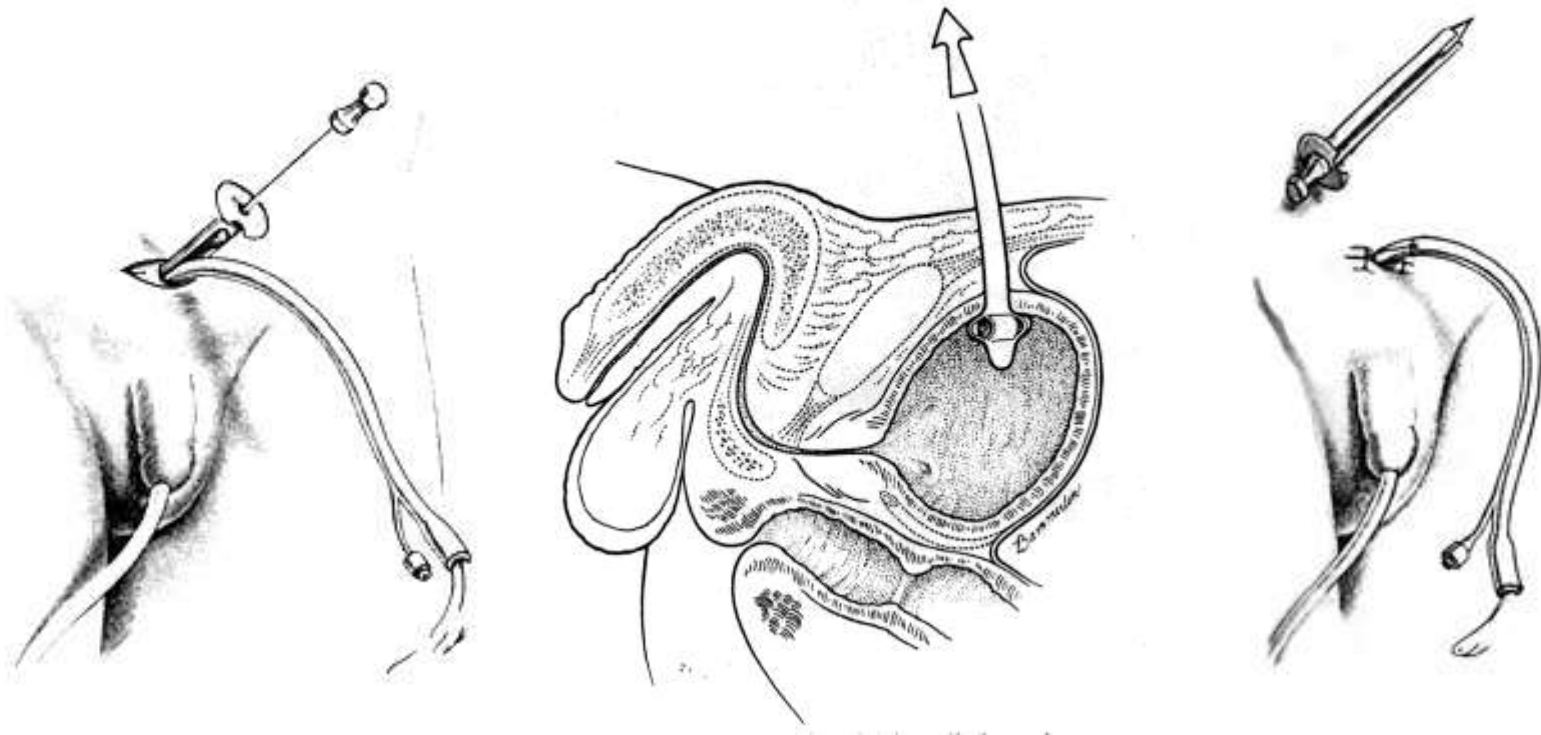


Malecot cath atau  
NGT ch 8-10

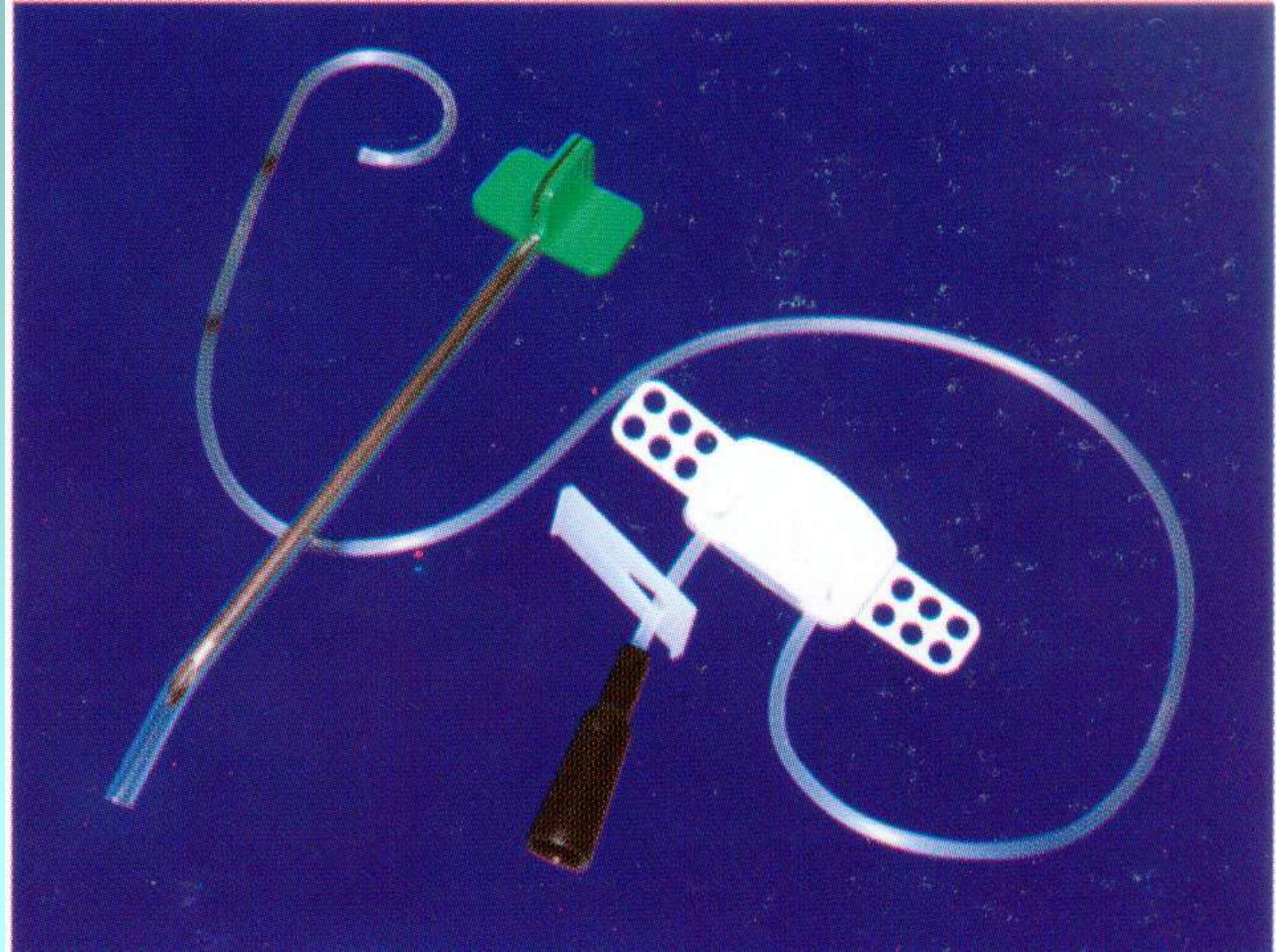
A

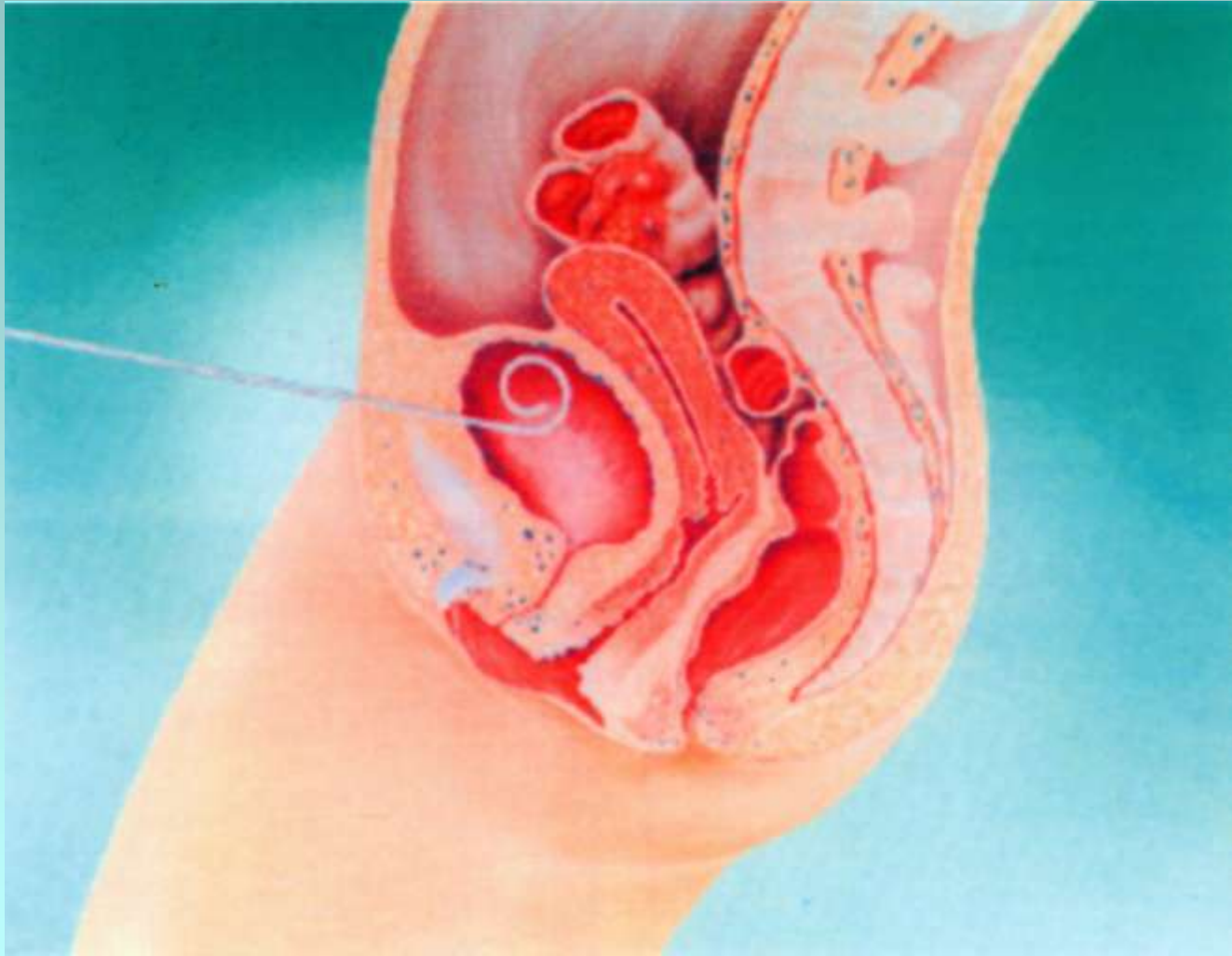


- Cystostomy Percutan
- Trocar khusus + Foley Ch 12



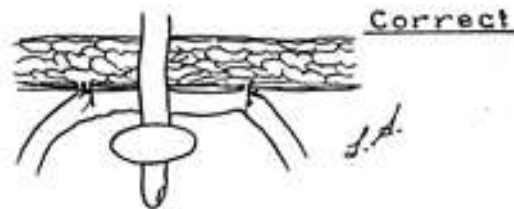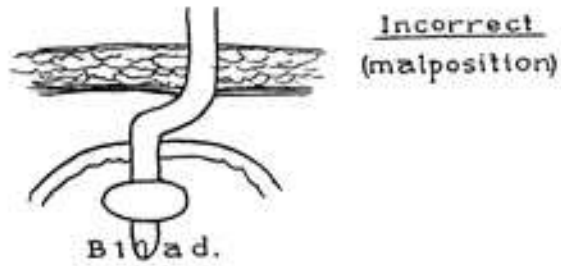
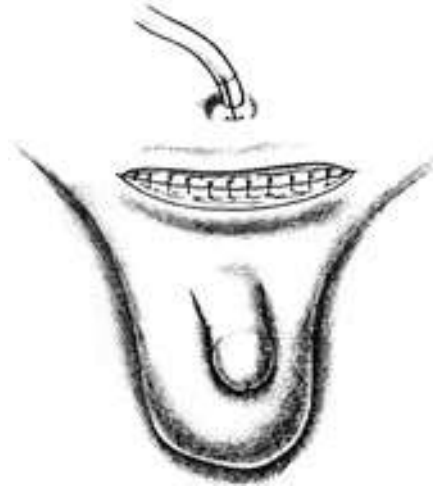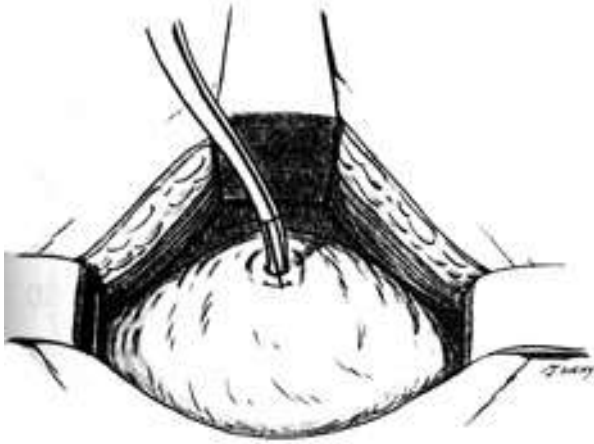- Cytostomy dengan Cystofix







- Open Cytostomy





*TERIMA*

---

*KASIH*