Embryology

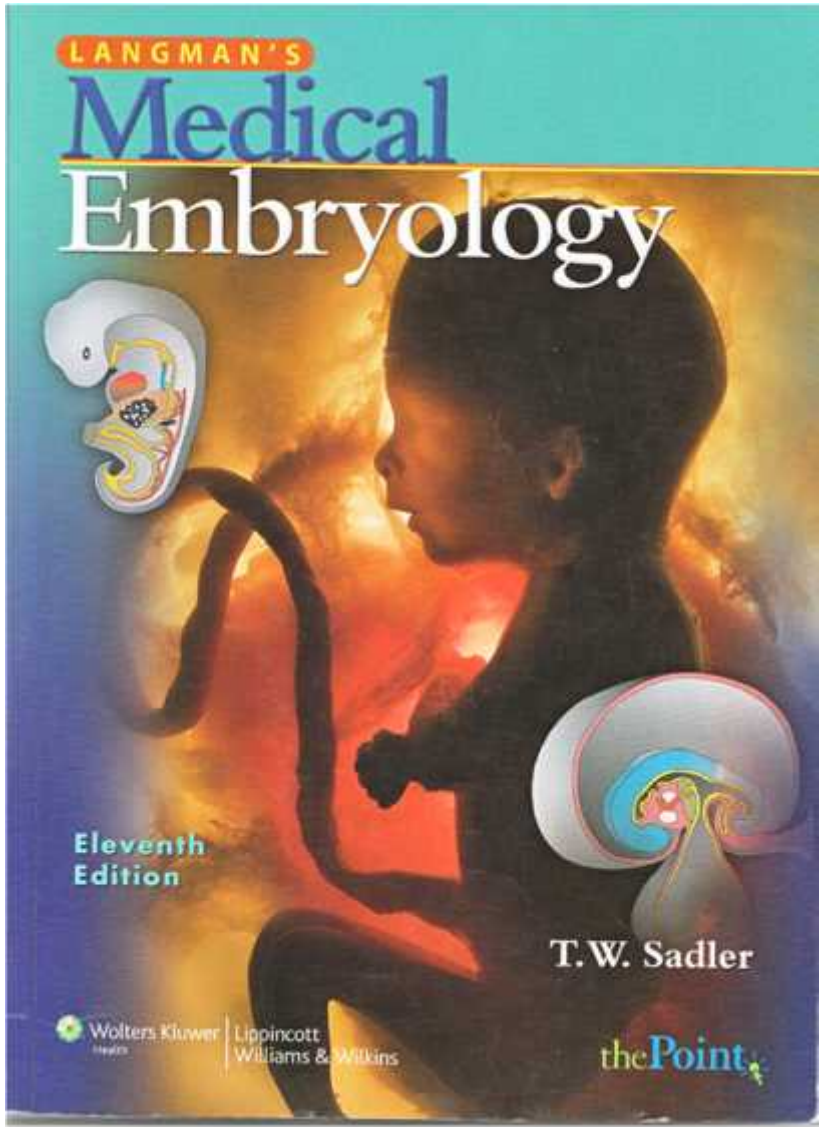

J. Matthew Velkey, Ph.D.

matt.velkey@duke.edu

452A Davison, Duke South

Textbook: ***Langmans's Medical Embryology, 11th ed.***

When possible, lectures will be recorded and there may be notes for **some** lectures, but still NOT a substitute for reading the text.

Completing assigned reading prior to class is essential for sessions where a READINESS ASSESSMENT is scheduled.

Overall goal: understand the fundamental processes by which the adult form is produced and the clinical consequences that arise from abnormal development.

Follicle Maturation and Ovulation

Oocytes

~2 million at birth
~40,000 at puberty
~400 ovulated over lifetime

Leutinizing Hormone surge (from pituitary gland) causes changes in tissues and within follicle:

- Swelling within follicle due to increased hyaluronan
- Matrix metalloproteinases degrade surrounding tissue causing rupture of follicle

Egg and surrounding cells (corona radiata) ejected into peritoneum

Corona radiata provides bulk to facilitate capture of egg.

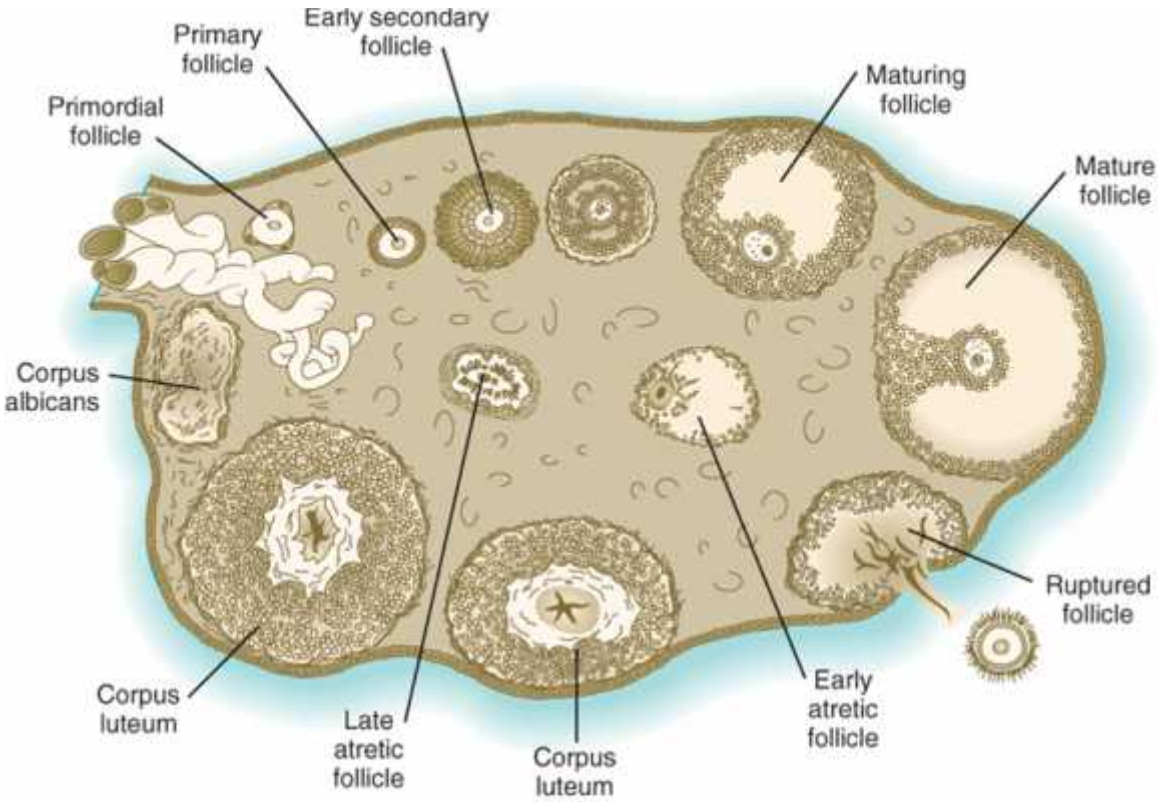

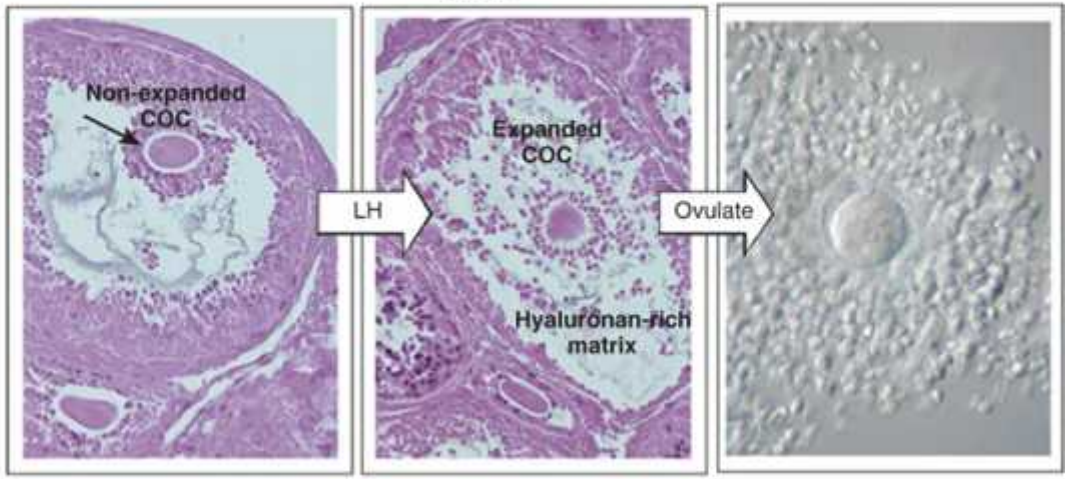

The egg (and corona radiata) at ovulation

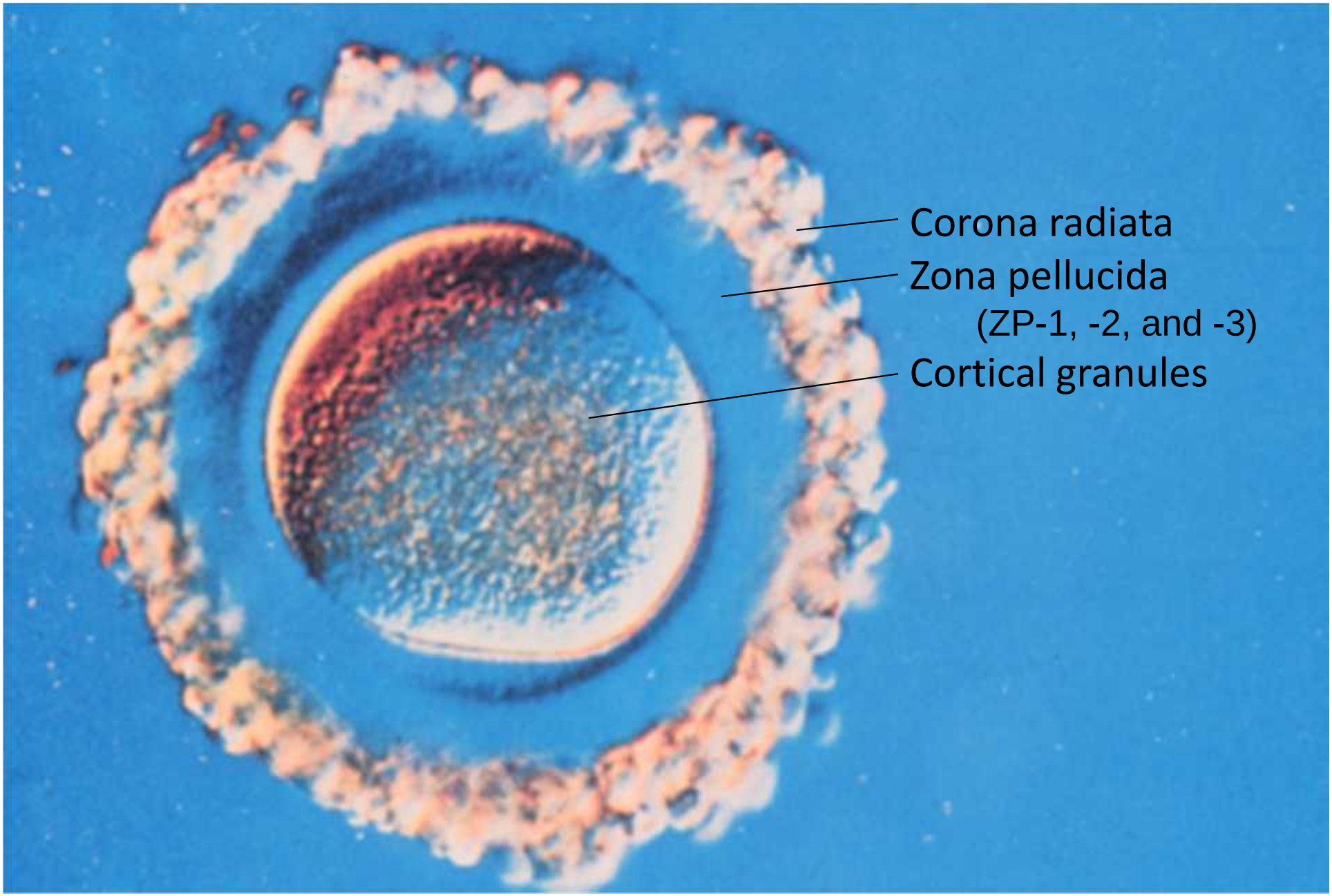

Transport through the oviduct

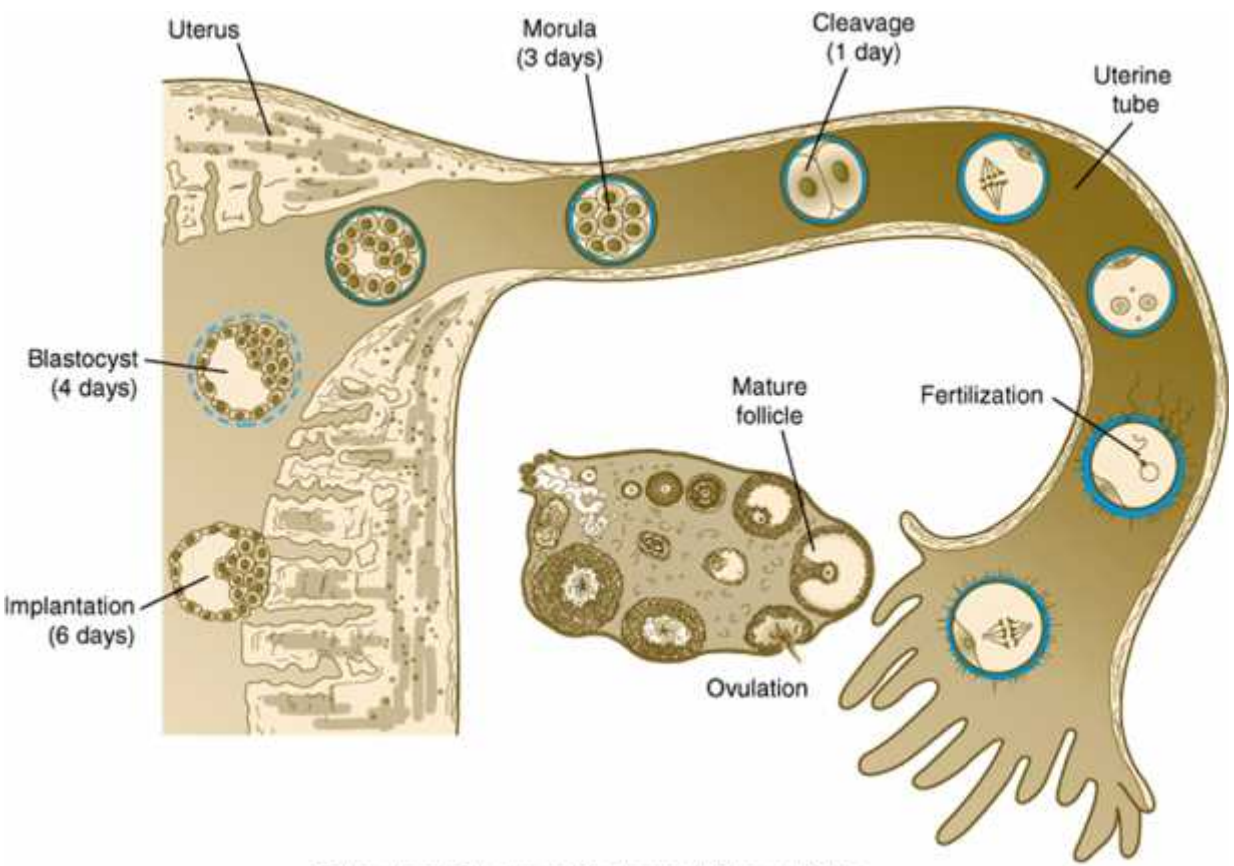

At around the midpoint of the menstrual cycle (~day 14), a single egg is **ovulated** and swept into the oviduct.

Fertilization usually occurs in the **ampulla** of the oviduct within 24 hrs. of ovulation.

Series of cleavage and differentiation events results in the formation of a **blastocyst** by the 4th embryonic day.

- **Inner cell mass** generates **embryonic tissues**
- Outer **trophectoderm** generates **placental tissues**

Implantation into the uterine wall occurs ~6th embryonic day (day 20 of the menstrual cycle)

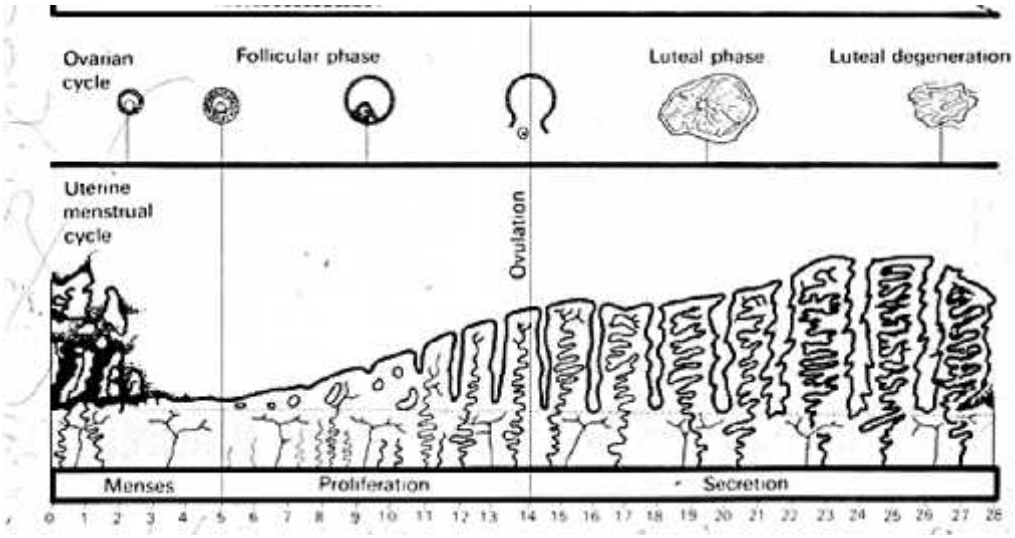

Timing of pregnancy

Embryologists

Fertilization age: moment of fertilization is dO

Division of pregnancy corresponding to development:

- 0-3 weeks –early development
- 3-8 weeks –embryonic period (organogenesis)
- 8 wks-term –fetal period

Total gestation time = 38 weeks

Clinicians

Menstrual age: last menses is dO

Division of pregnancy into trimesters

Total gestation time = 40 weeks

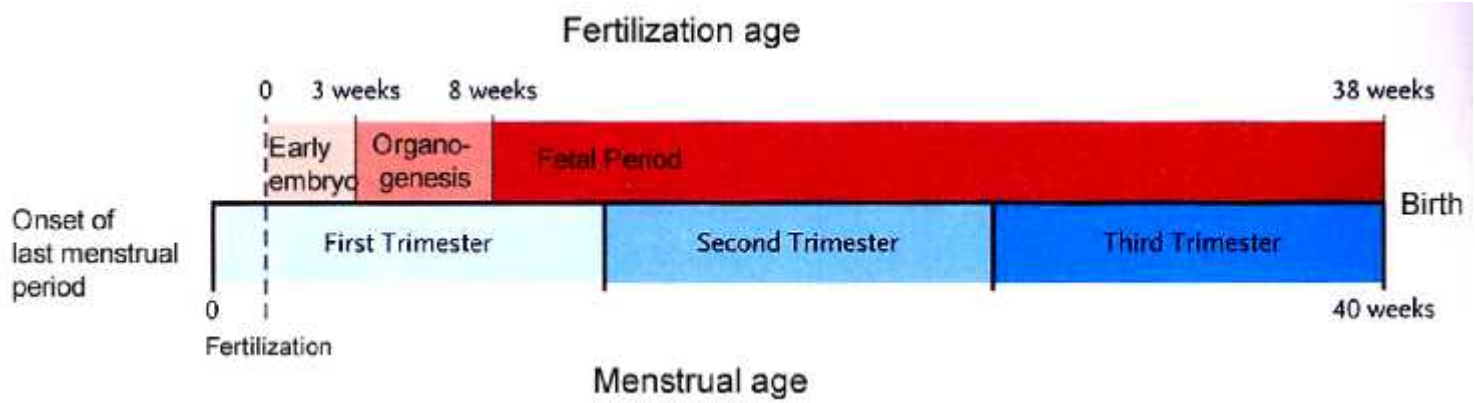

Fertilization is a multi-step process whereby multiple sperm bind to the corona radiata, but only a single sperm usually fertilizes the egg

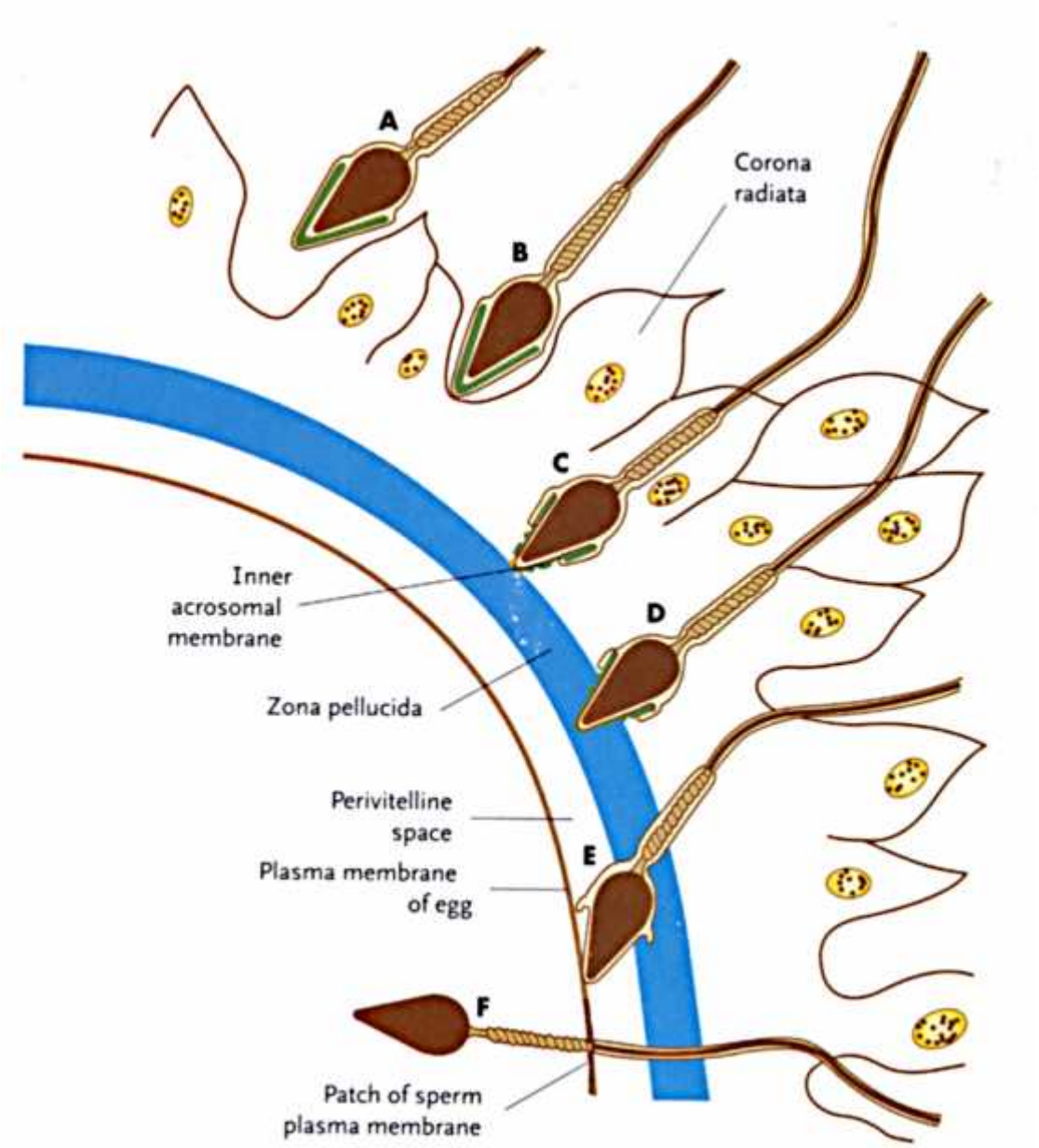

1. Acrosome Rx

sperm bind to ZP proteins in the zona pellucida; this initiates the release of enzymes from the sperm allowing it to burrow through the zona pellucida.

2. Zona Rx

binding of the sperm and egg plasma membranes initiates Ca+ influx into the egg and release of **cortical granules** from the egg that block other sperm from fertilizing the egg.

This so-called cortical reaction prevents other sperm from fertilizing the egg (aka “polyspermy”)

Cortical granule enzymes digest ZP proteins so other sperm can no longer bind.

Hyaluronic acid and other proteoglycans are also released that become hydrated and swell, thus pushing the other sperm away.

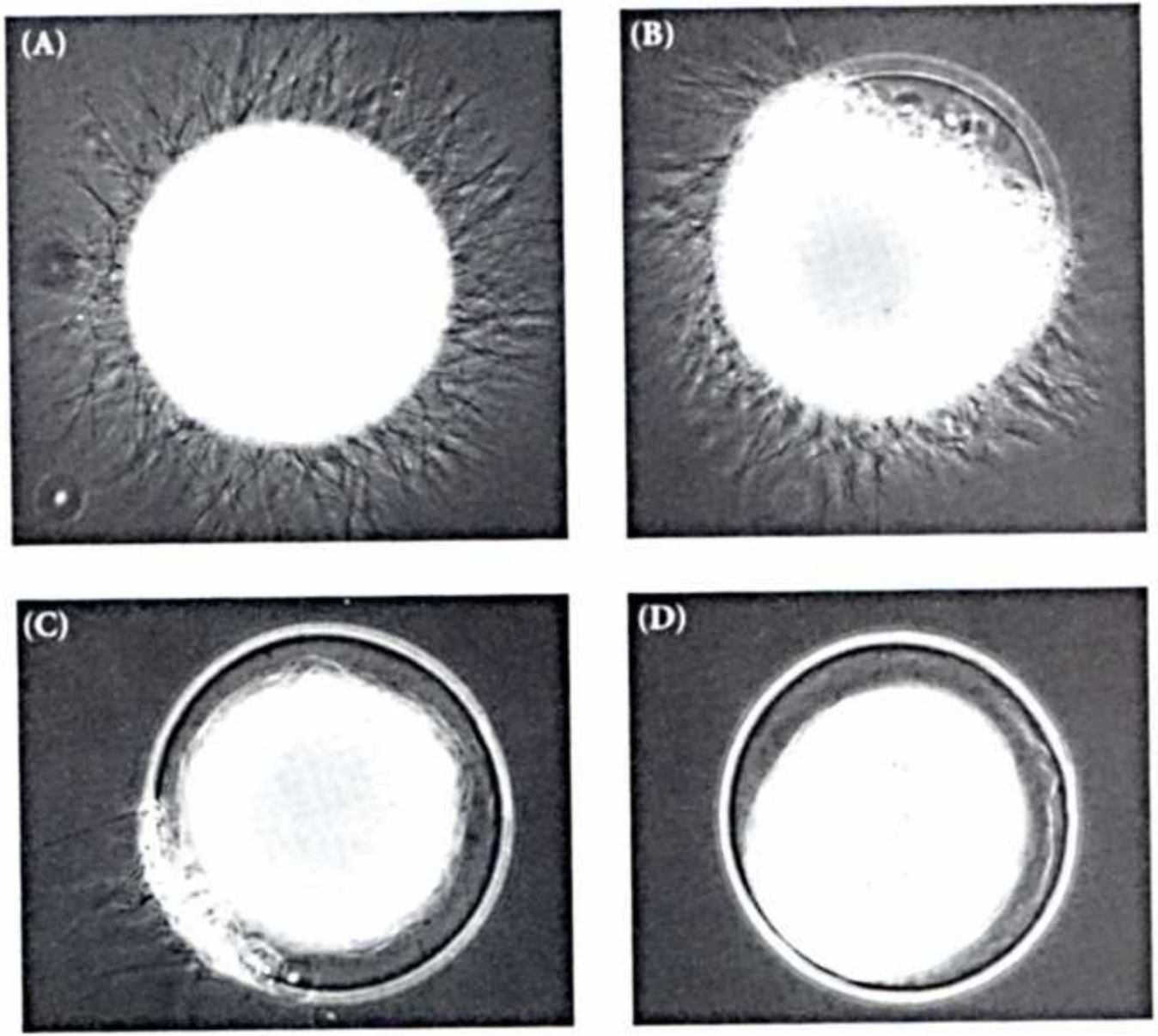

Fertilization

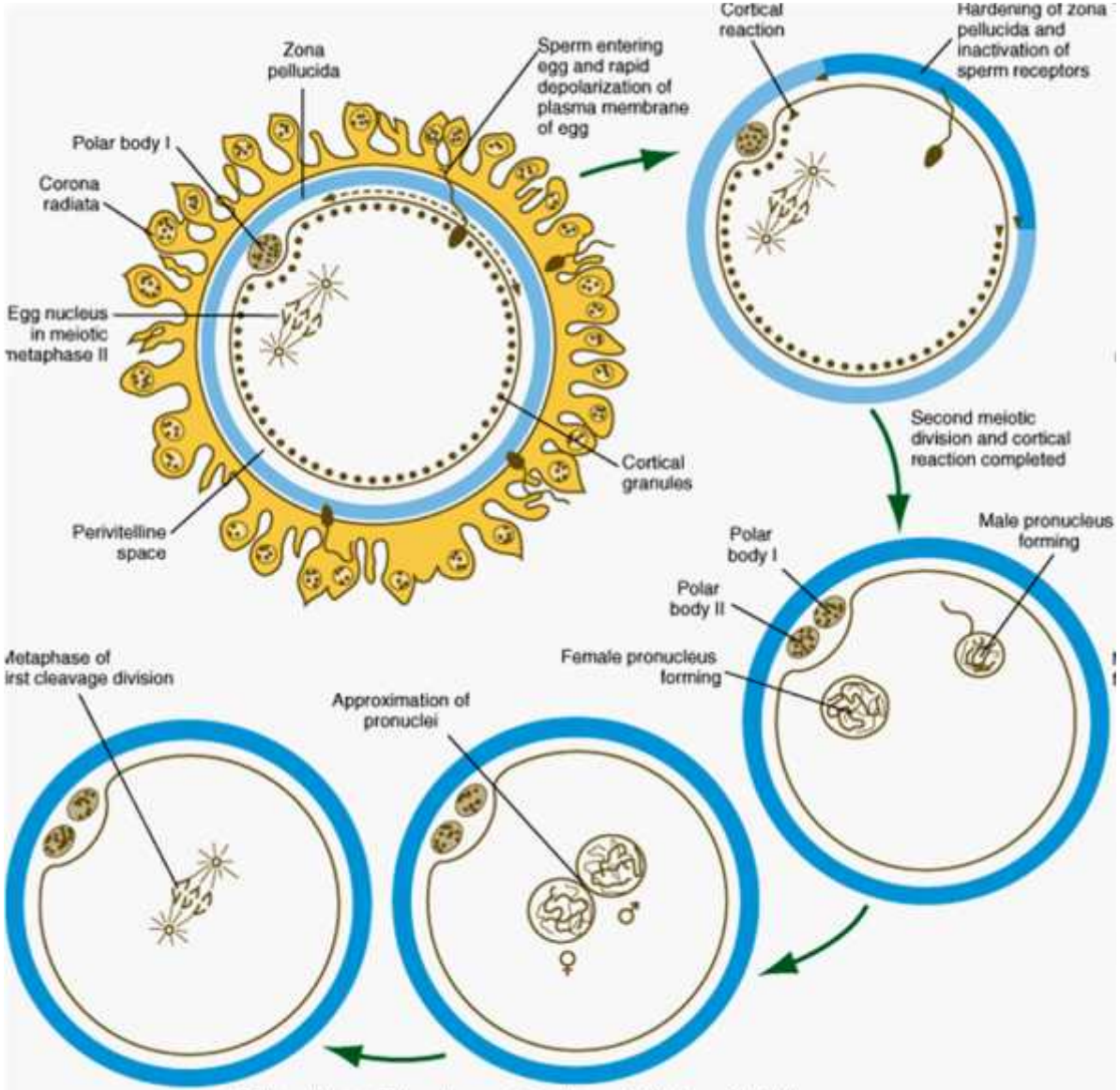

Meiosis II complete

Formation of male and female pronuclei

Decondensation of male chromosomes

Fusion of pronuclei

Zygote

Week 1: days 1-6

- Fertilization, day 1
- Cleavage, day 2-3
- Compaction, day 3
- Formation of blastocyst, day 4
- Ends with implantation, day 6

Fertilized egg (zygote)

Fertilized egg
2 polar bodies
2 pronuclei

Day 1
0.1 mm

Cleavage

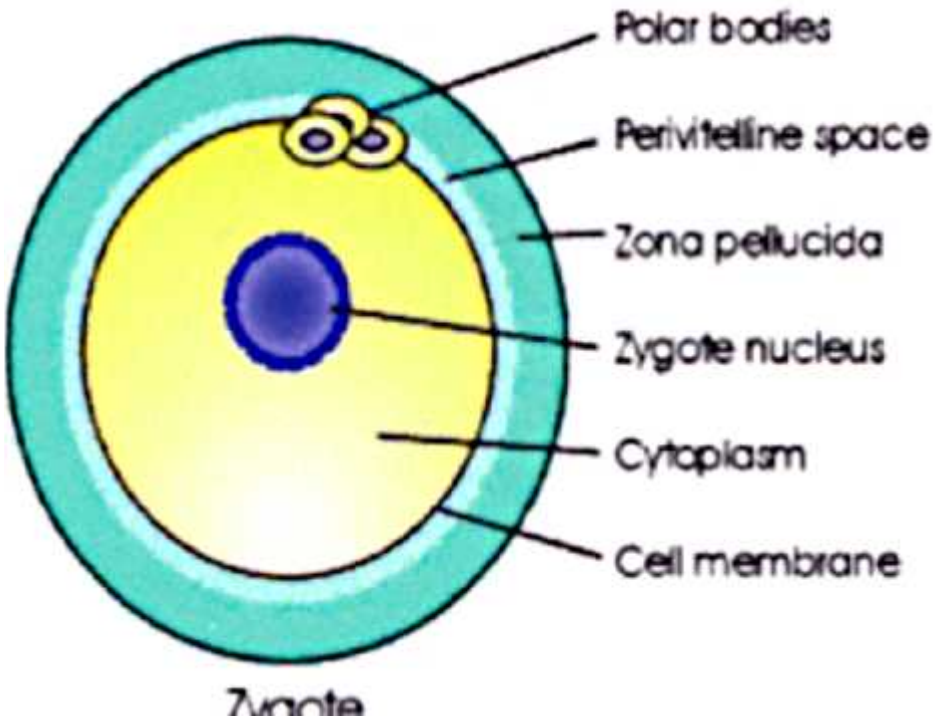

Cleavage = cell division

Goals: grow unicellular zygote to multicellular embryo.
Divisions are slow: 12 - 24h ea
No growth of the embryo- stays at ~100 um in diameter
Divisions are not synchronous

Cleavage begins about 24h after pronuclear fusion

2 Cell Stage

Individual cells = blastomeres

Mitotic divisions maintain
2N (diploid) complement

Cells become <u>smaller</u>

Blastomeres are equivalent (aka totipotent).

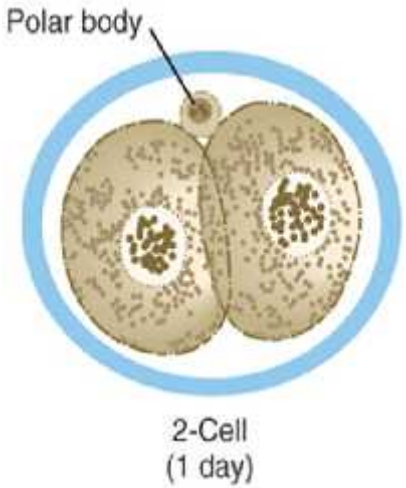

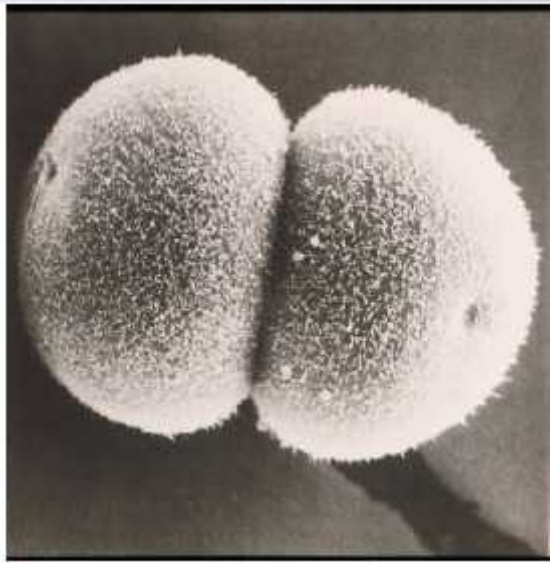

4 cell; second cleavage

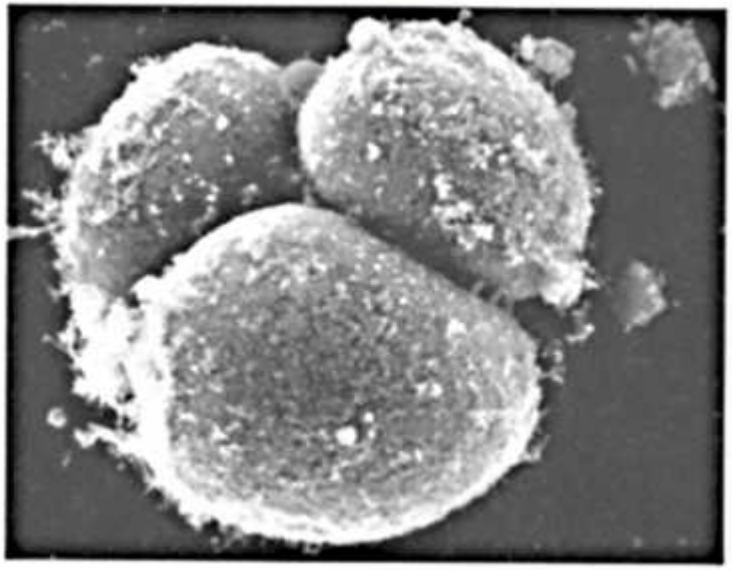

4 equivalent blastomeres

Still in zona pellucida

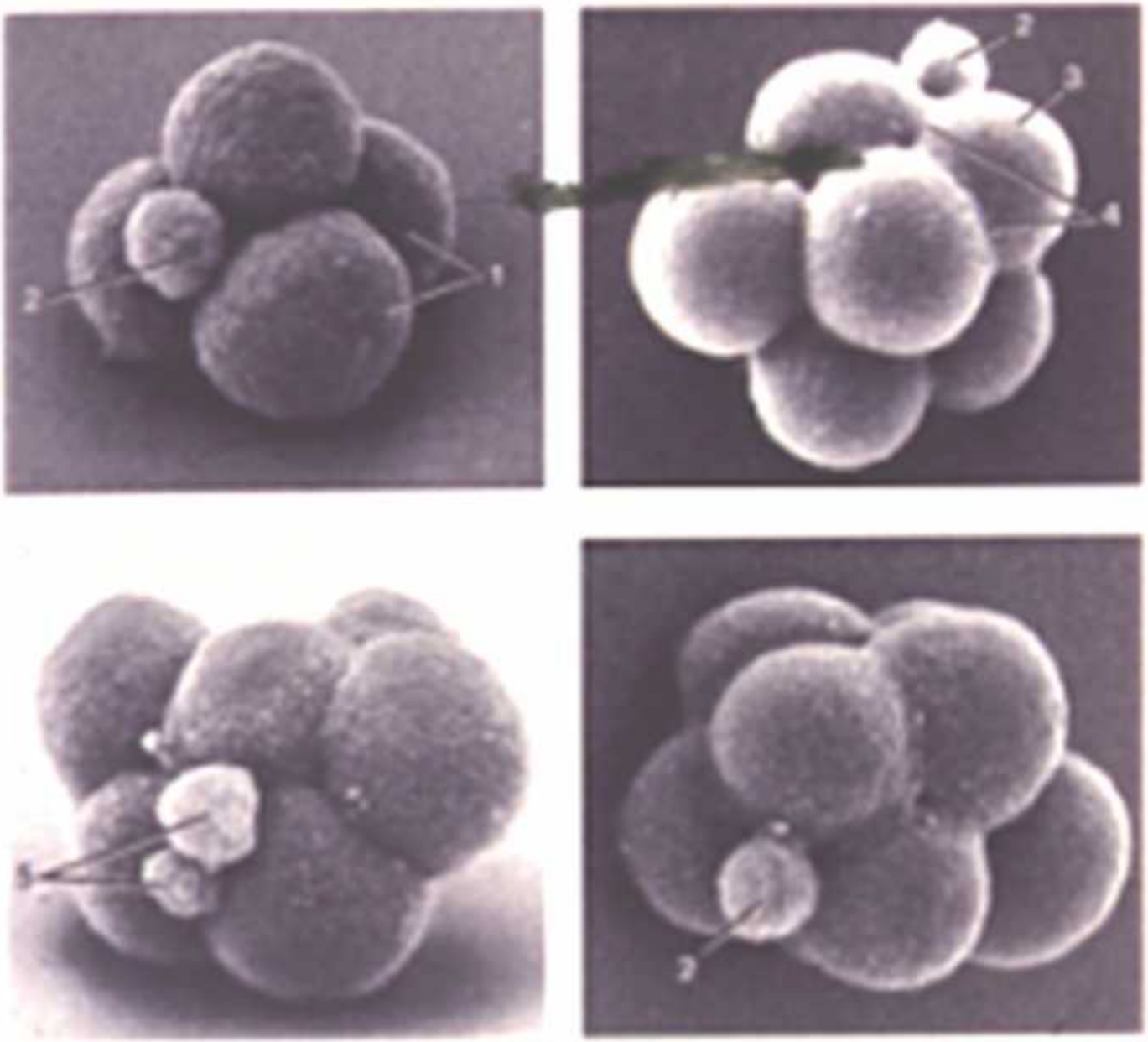

8 Cell; third cleavage

Blastomeres still equivalent

Embryo undergoes **compaction** after 8-cell stage: first differentiation of embryonic lineages

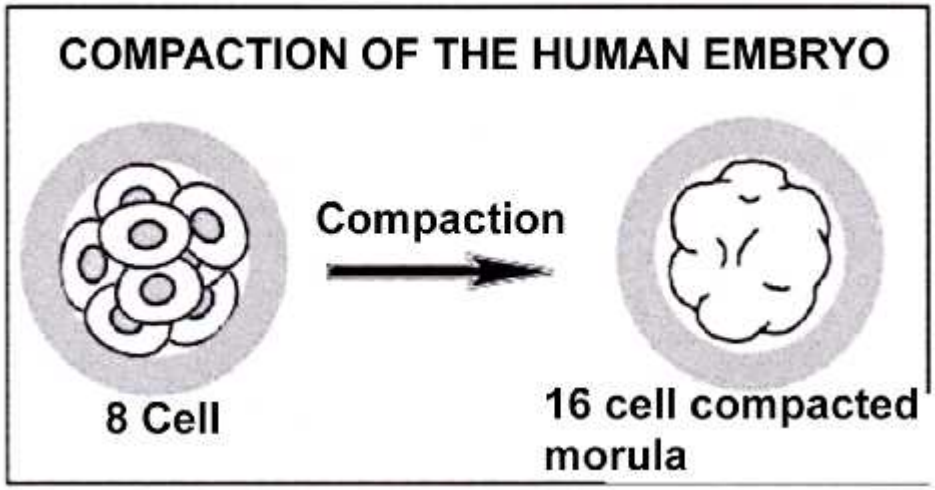

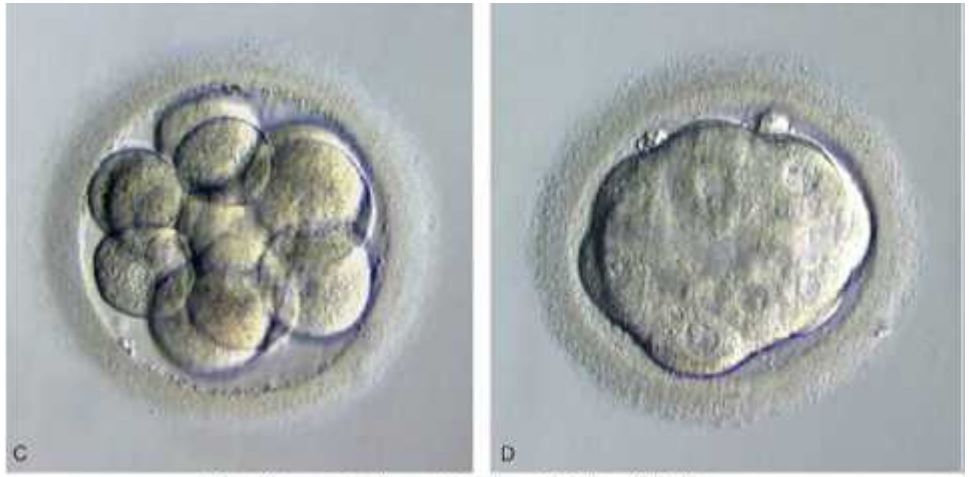

Caused by increased cell-cell adhesion

Cells that are forced to the outside of the morula are destined to become **trophoblast**--cells that will form **placenta**

The **inner cells** will form the embryo proper and are called the **inner cell mass** (ICM).

Formation of the blastocyst

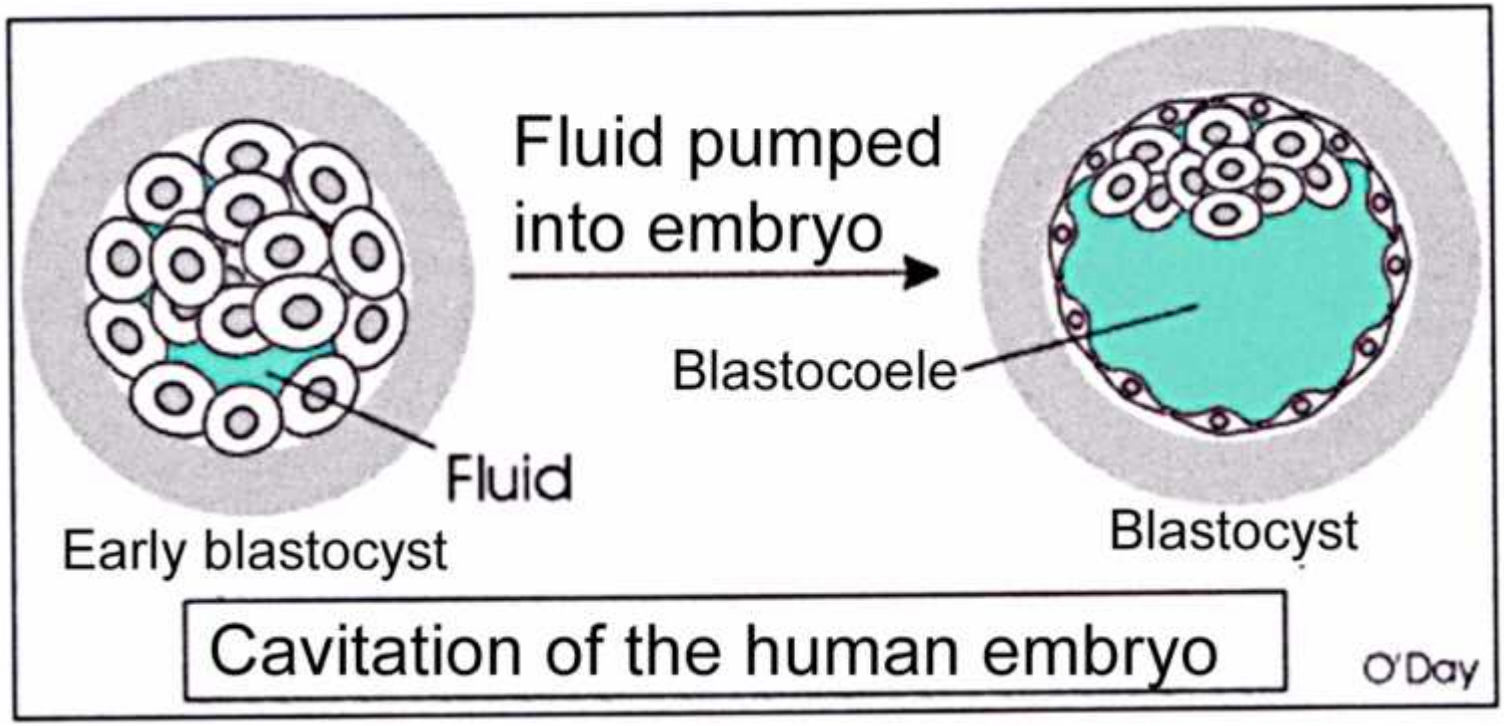

Sodium channels appear on the surface of the outer trophoblast cells; sodium and water are pumped into the forming blastocoele. Note that the embryo is still contained in the zona pellucida.

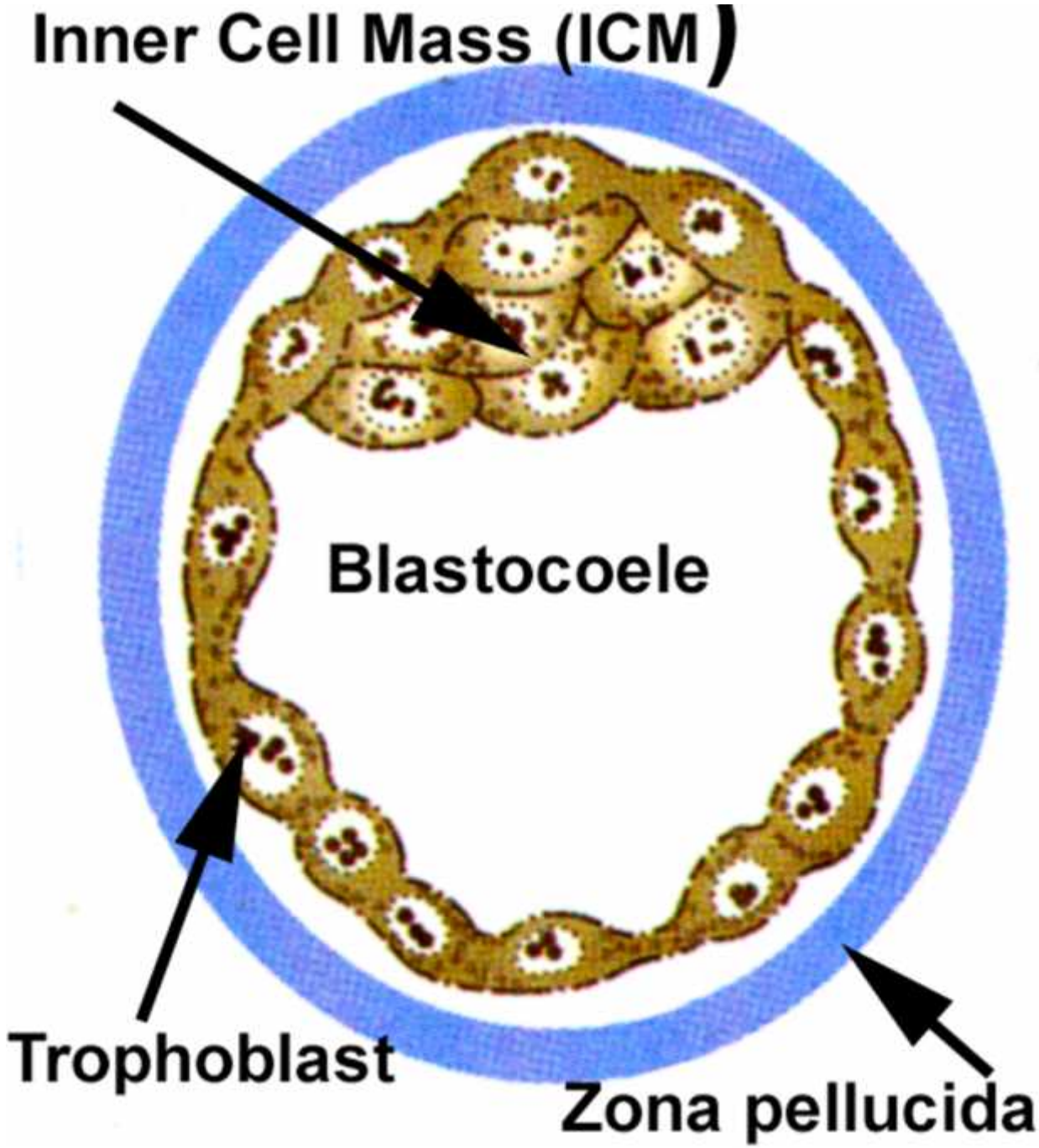
Inner Cell Mass (ICM)
Blastocoele
Trophoblast
Zona pellucida

Early blastocyst
Day 3

Later blastocyst
Day 5

Monozygotic twinning typically occurs during cleavage/blastocyst stages

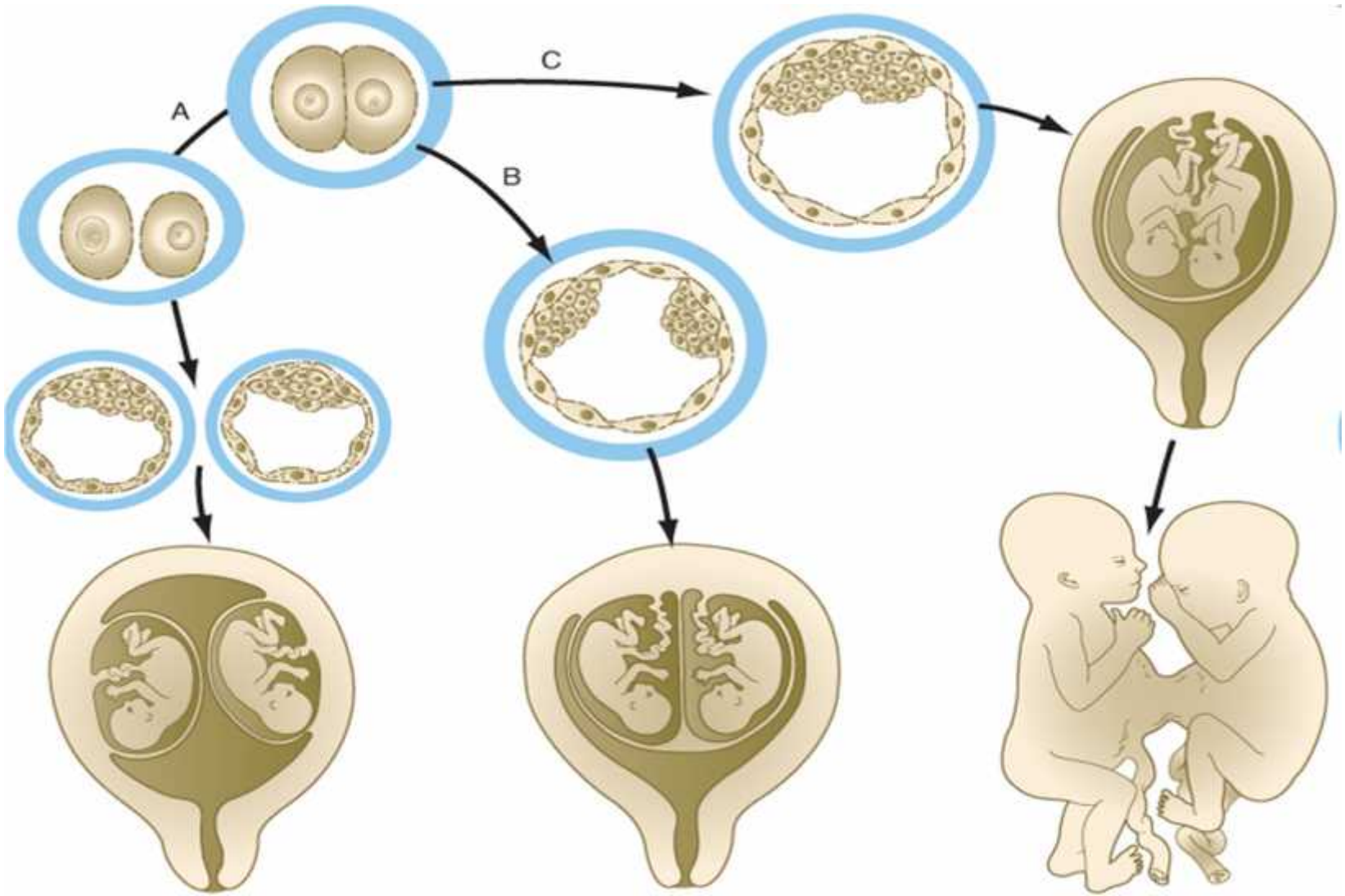

“Hatching” of the blastocyst: preparation for implantation

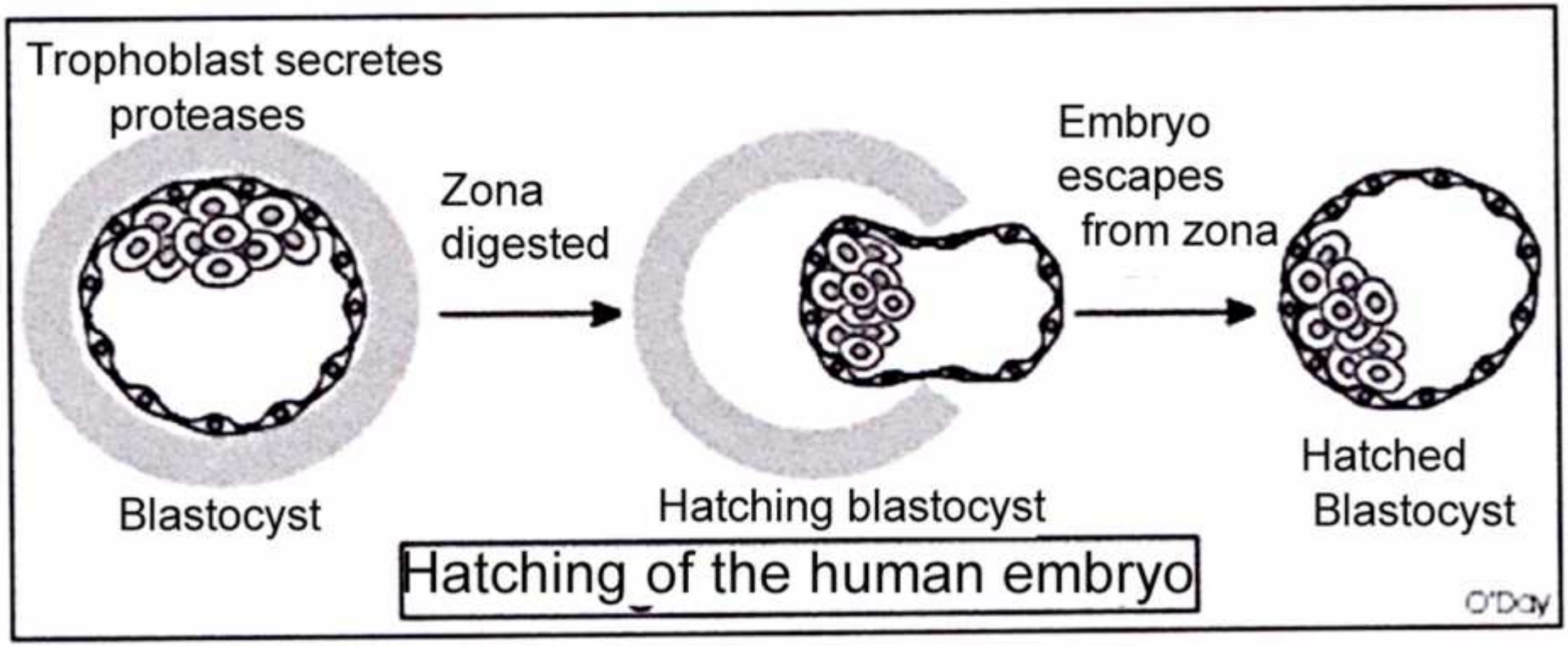

Hatching of the embryo from the zona pellucida occurs just prior to implantation. Occasionally, the inability to hatch results in infertility, and premature hatching can result in abnormal implantation in the uterine tube.

Ectopic Implantation

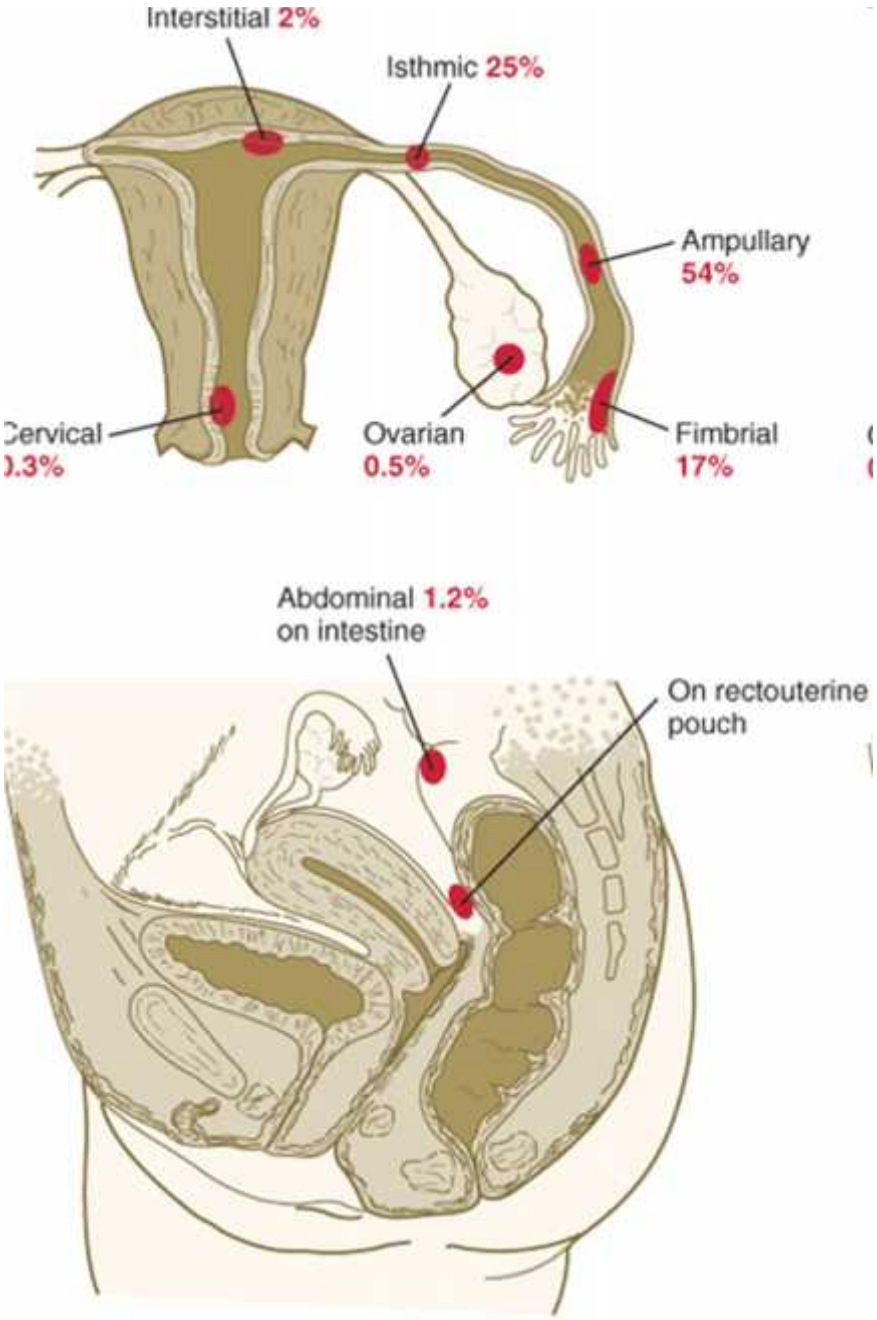

Implantation somewhere other than upper portion of uterus

"Rupture" can lead to life-threatening hemorrhage

Tubal pregnancy

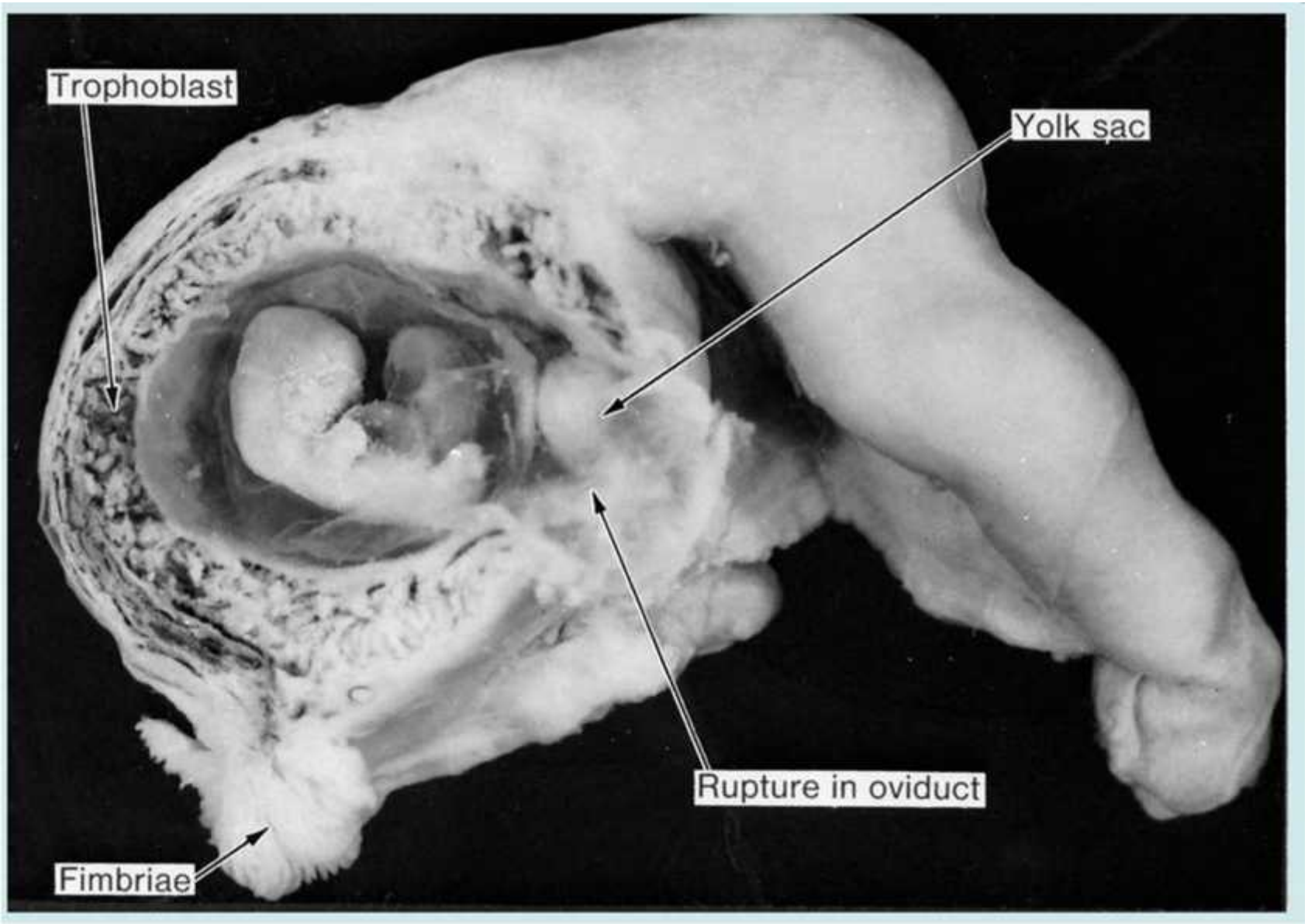

Week 2: days 7-14 implantation

- Implanted embryo becomes more deeply embedded in endometrium
- Further development of trophoblast into placenta
- Development of a bi-laminar embryo, amniotic cavity, and yolk sac.

Implantation and placentation (day 8)

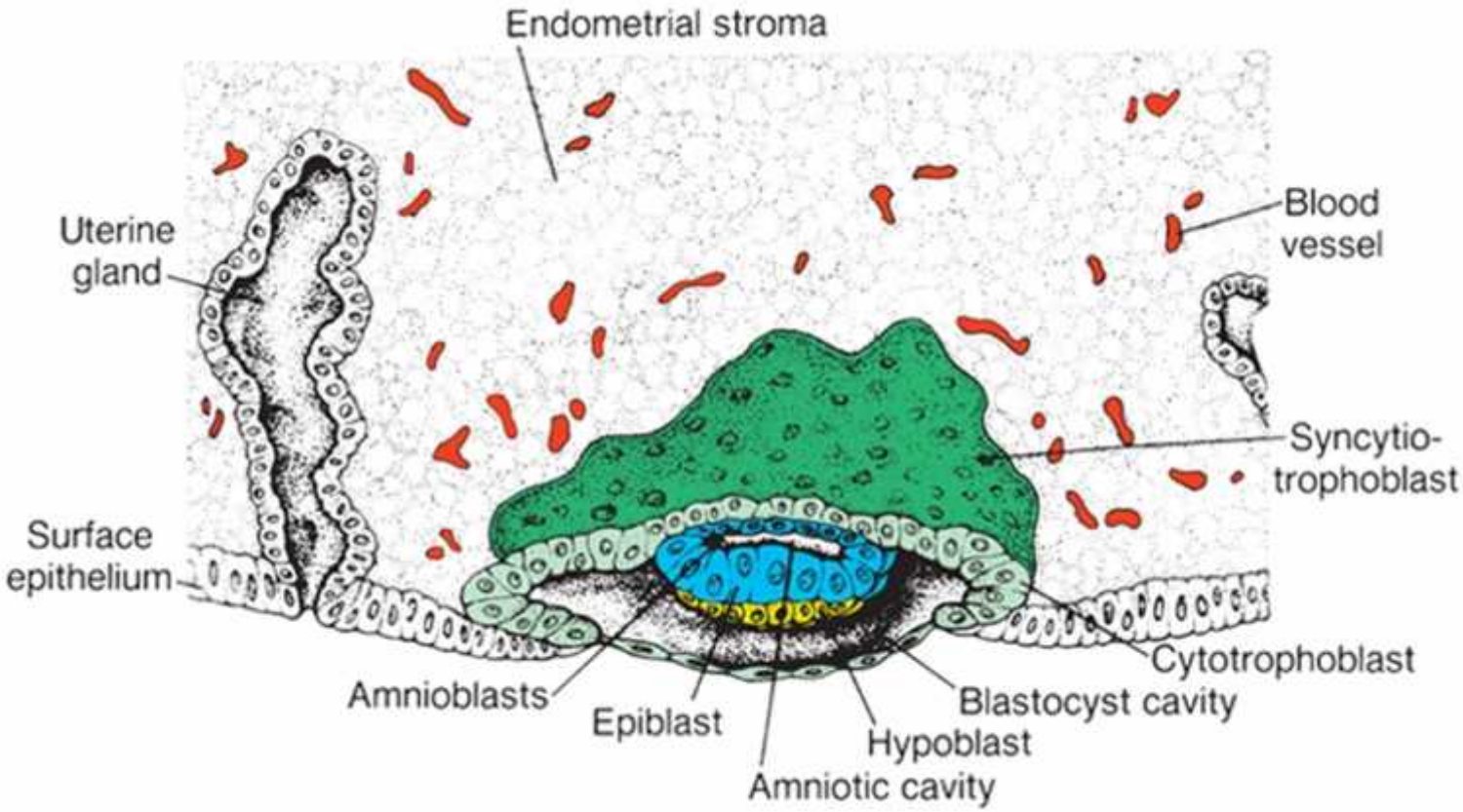

Trophoblast further differentiates and invades maternal tissues

- Cytotrophoblast: stem cell population
- Syncytiotrophoblast: invasive fused cells (syncytium) derived from cytotrophoblast
- Breaks maternal capillaries, trophoblastic lacunae fill with maternal blood

Inner cell mass divides into epiblast and hypoblast:

- Epiblast contributes to forming the overlying amniotic membrane and amniotic cavity
- Hypoblast contributes to forming the underlying yolk sac.

Implantation and placentation (day 9)

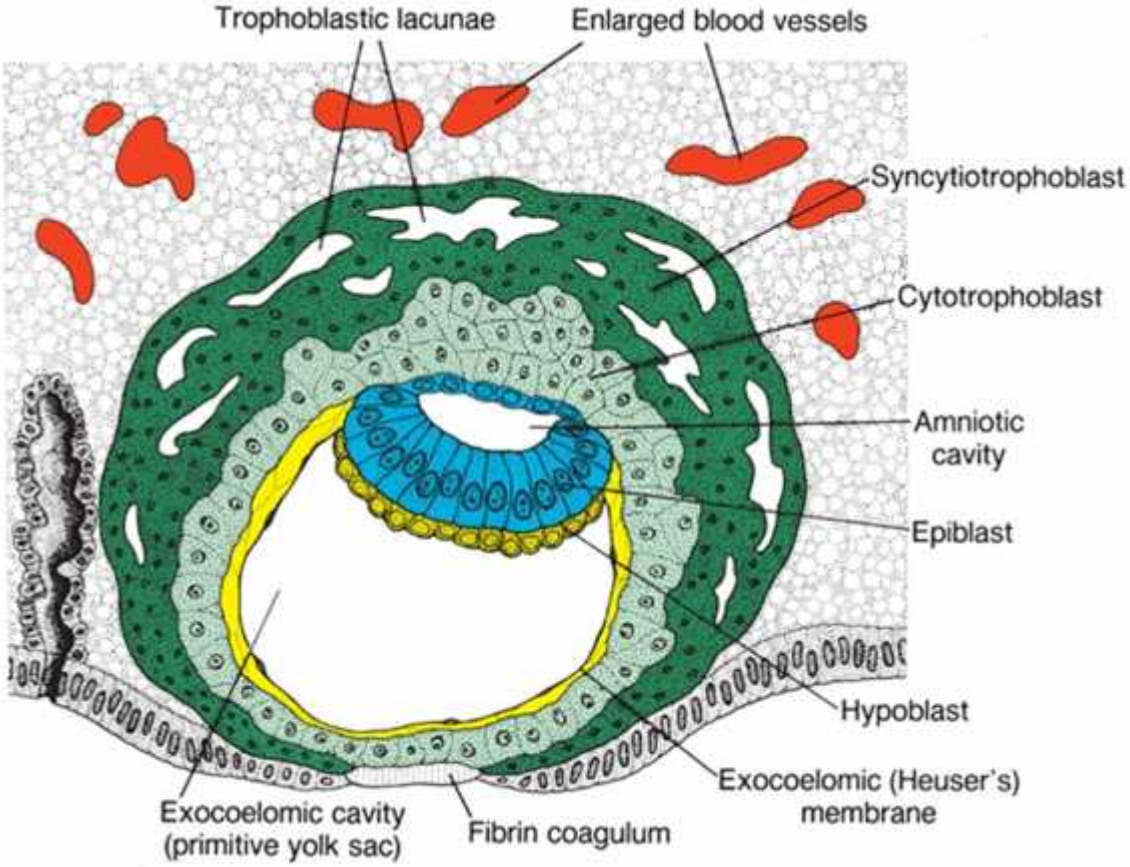

Trophoblast further differentiates and invades maternal tissues

- Cytotrophoblast: stem cell population
- Syncytiotrophoblast: invasive fused cells (syncytium) derived from cytotrophoblast
- Breaks maternal capillaries, trophoblastic lacunae fill with maternal blood

Inner cell mass divides into epiblast and hypoblast:

- Epiblast contributes to forming the overlying amniotic membrane and amniotic cavity
- Hypoblast contributes to forming the underlying yolk sac.

Implantation and placentation (day 12)

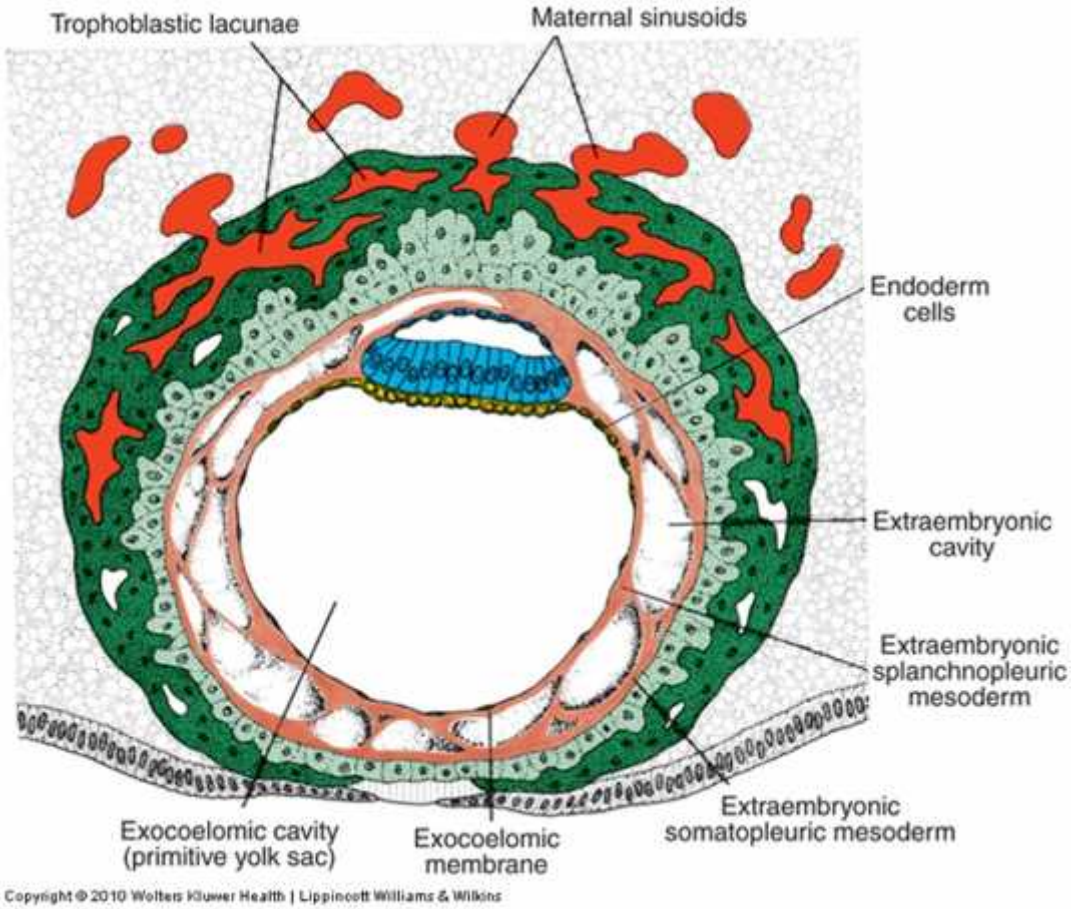

Trophoblast further differentiates and invades maternal tissues

- Cytotrophoblast: stem cell population
- Syncytiotrophoblast: invasive fused cells (syncytium) derived from cytotrophoblast
- Breaks maternal capillaries, trophoblastic lacunae fill with maternal blood

Inner cell mass divides into epiblast and hypoblast:

- Epiblast contributes to forming the overlying amniotic membrane and amniotic cavity
- Hypoblast contributes to forming the underlying yolk sac.

Implantation and placentation (day 13)

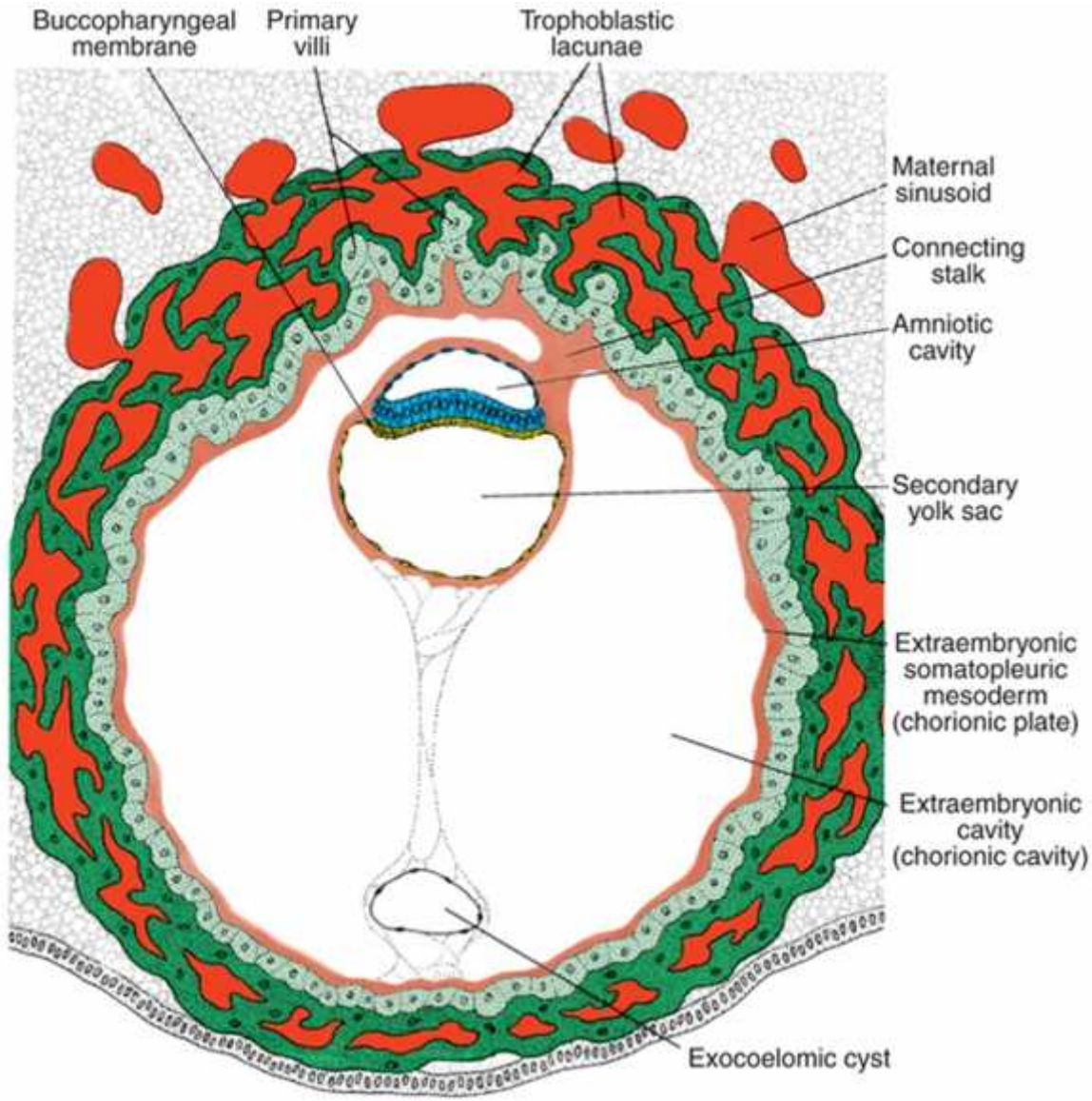

Trophoblast further differentiates and invades maternal tissues

- Cytotrophoblast: stem cell population
- Syncytiotrophoblast: invasive fused cells (syncytium) derived from cytotrophoblast
- Breaks maternal capillaries, trophoblastic lacunae fill with maternal blood

Inner cell mass divides into epiblast and hypoblast:

- Epiblast contributes to forming the overlying amniotic membrane and amniotic cavity
- Hypoblast contributes to forming the underlying yolk sac.

Week 3: Days 14-21

- Two layer germ disc
- Primitive streak forms
- Gastrulation forms tri-laminar embryo
- Neural induction
- Left-right asymmetry
- 0.4mm - 2.0mm

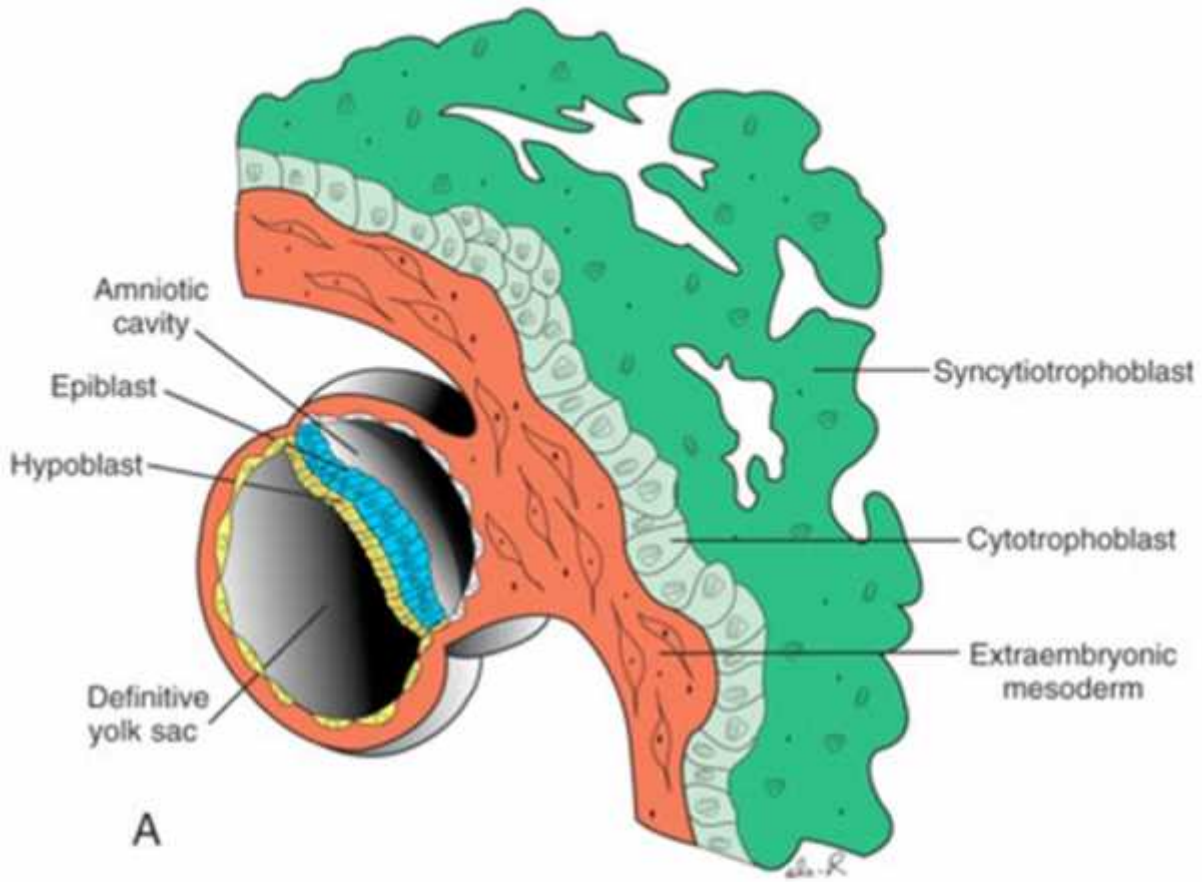
Amniotic cavity
Epiblast
Hypoblast
Definitive yolk sac
Syncytiotrophoblast
Cytotrophoblast
Extraembryonic mesoderm
A

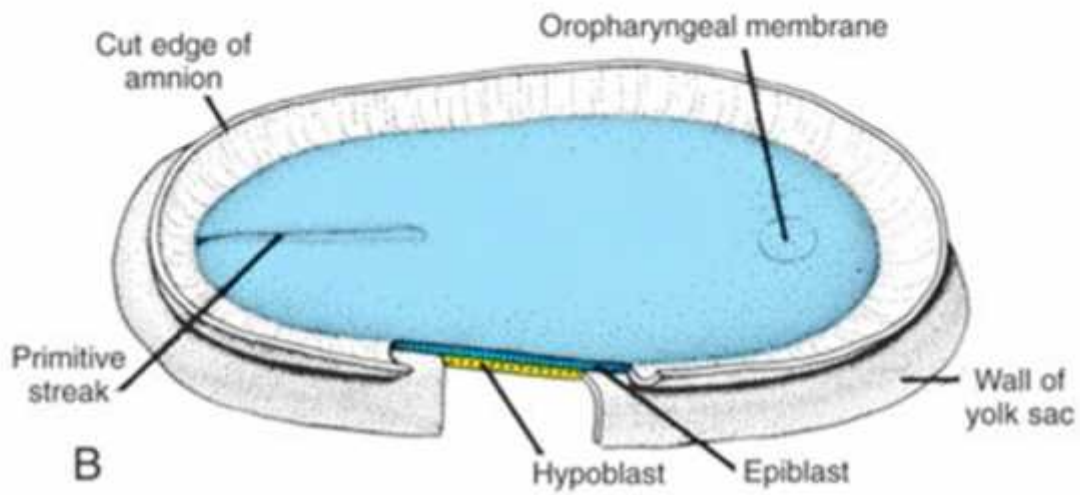
Cut edge of amnion
Oropharyngeal membrane
Primitive streak
Wall of yolk sac
B
Hypoblast
Epiblast

Gastrulation

At gastrulation the two layered epiblast is converted into the three primary embryonic germ layers:

- Ectoderm: outside, surrounds other layers later in development, generates **skin** and **nervous tissue**
- Mesoderm: middle layer, generates most of the **muscle, blood** and **connective tissues** of the body and placenta
- Endoderm: eventually most interior of embryo, generates the **epithelial lining** and associated **glands** of the **gut**, **lung**, and **urogenital tracts**

The human embryo at gastrulation

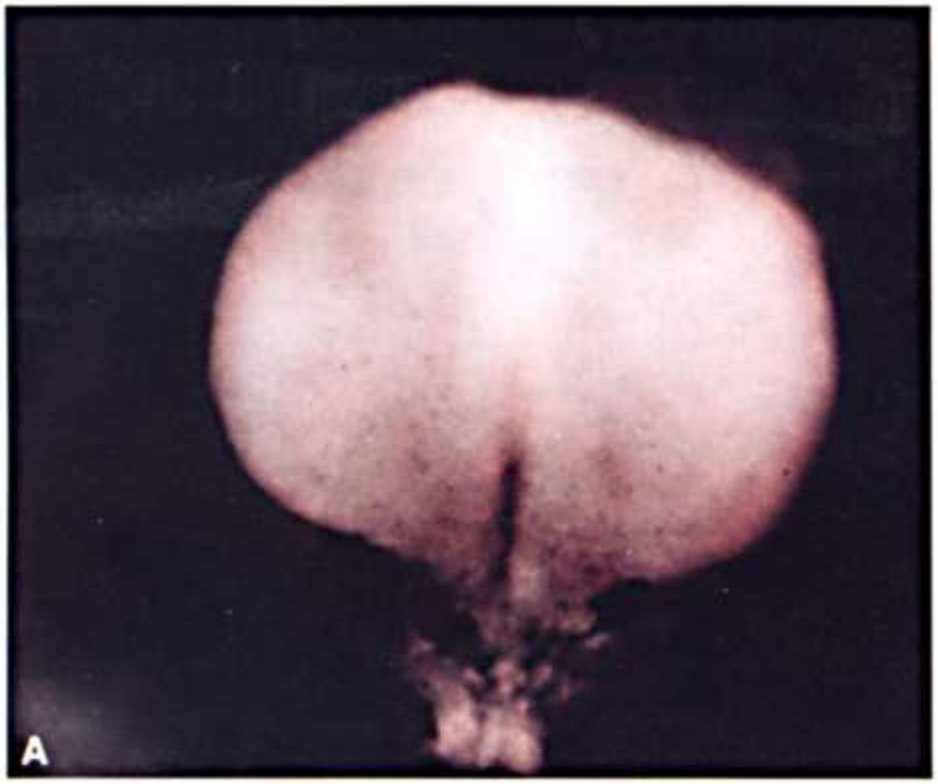

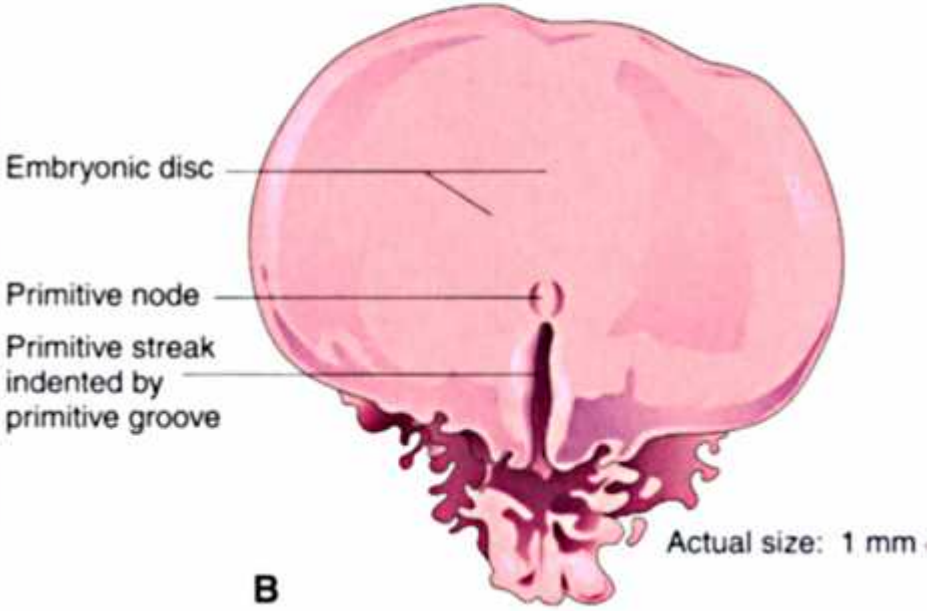

At gastrulation, primitive endoderm is replaced by definitive or embryonic endoderm <u>then</u> mesoderm is formed

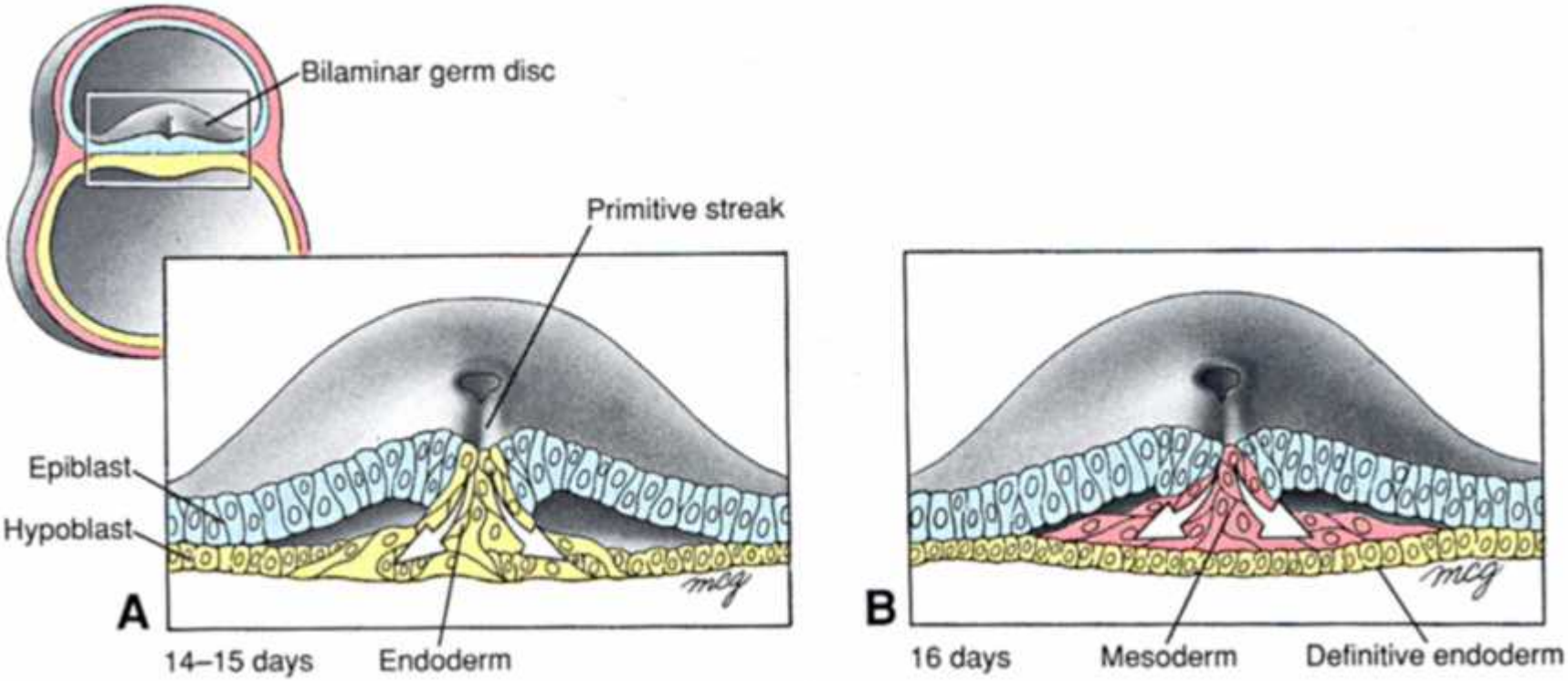

Cell movements during gastrulation

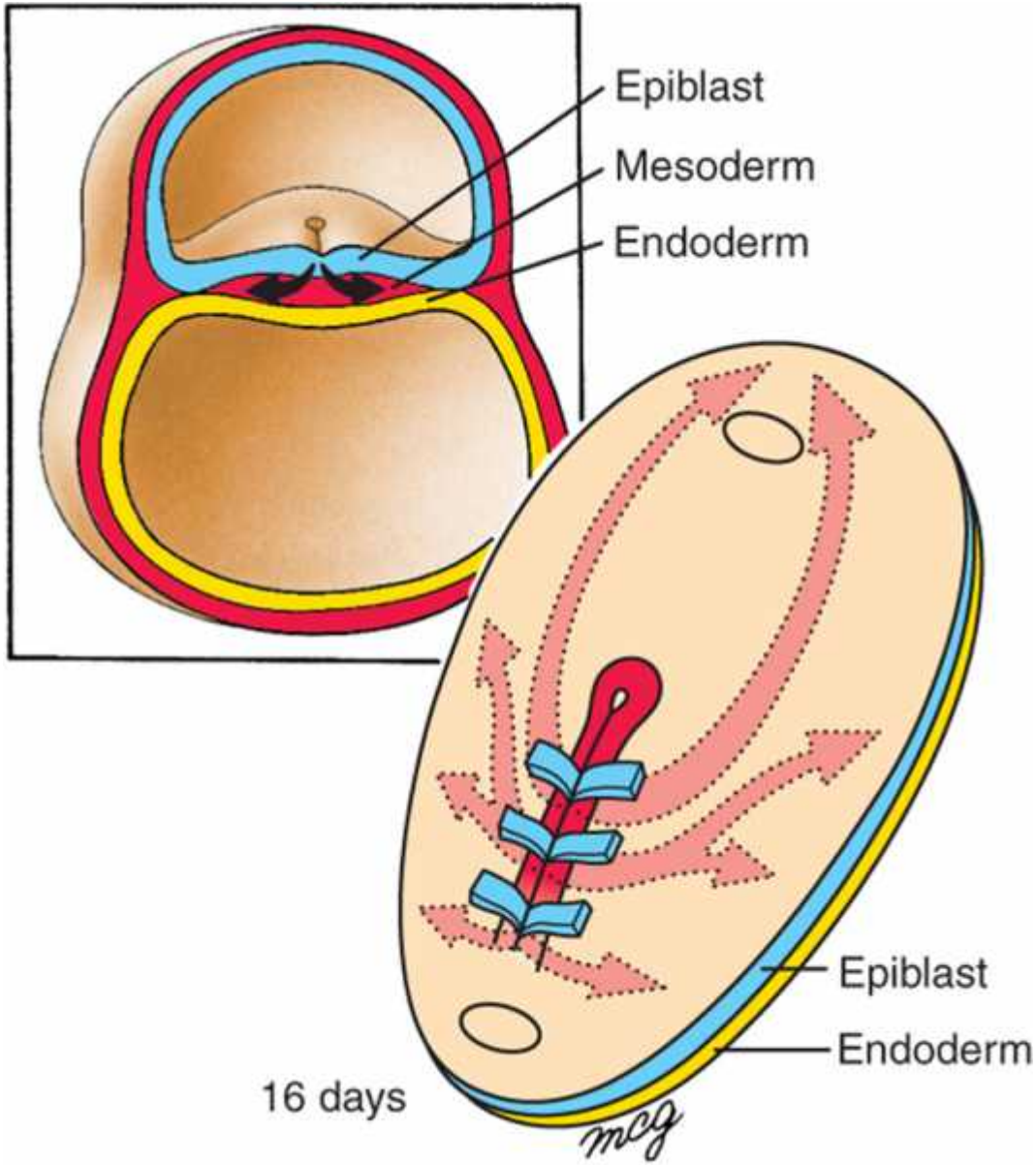

Mesoderm is patterned in a cranial to caudal gradient

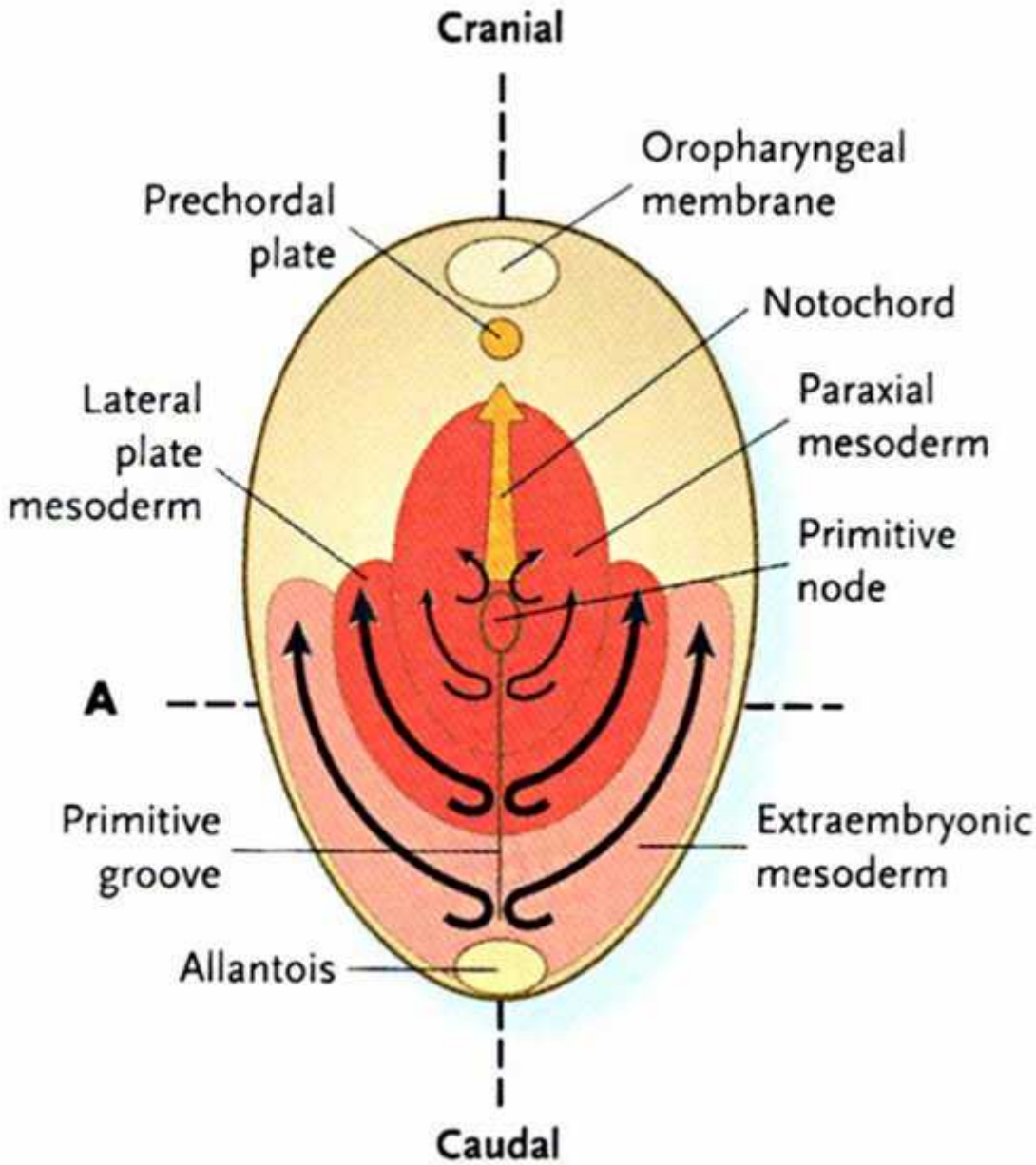

Axial mesoderm: passes through the node and migrates along the midline –forms the notochord

Paraxial mesoderm: passes just caudal to the node and migrates slightly laterally –forms cartilage, skeletal muscle, and dermis

Lateral plate mesoderm: passes more caudal and migrates more laterally –forms circulatory system and body cavity linings.

Extraembryonic mesoderm: passes most caudal and migrates most laterally –forms extraembryonic membranes and associated connective tissue & blood vessels.

Fate of the “axial” mesoderm

The **notochord** and **pre-chordal plate** develops from mesoderm arising from cells that passed directly through the node and migrated cranially along the midline

The notochord and pre-chordal plate are important signaling centers that pattern the overlying ectoderm and underlying endoderm.

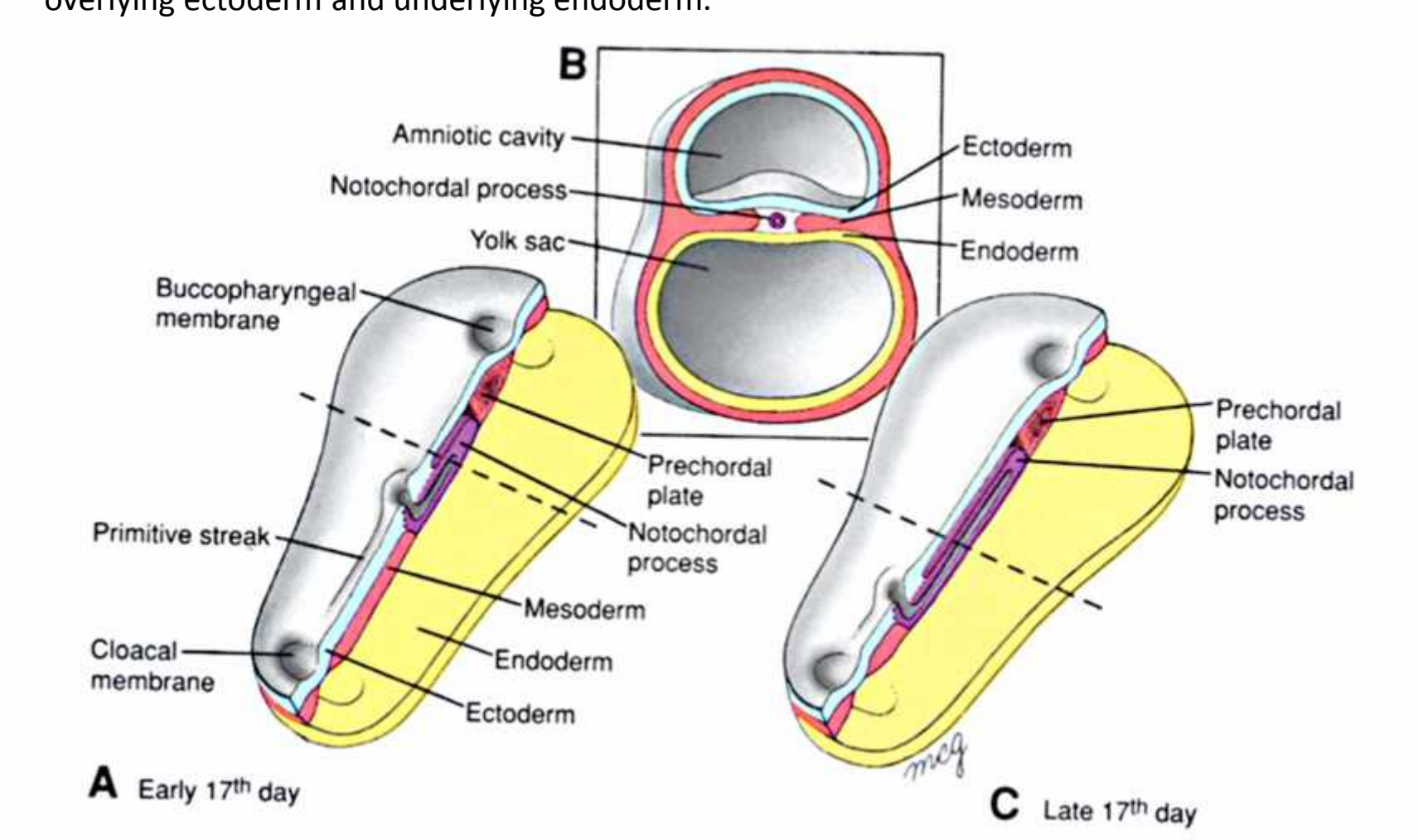

Major signaling centers at gastrulation:
the node and the anterior visceral endoderm (AVE)

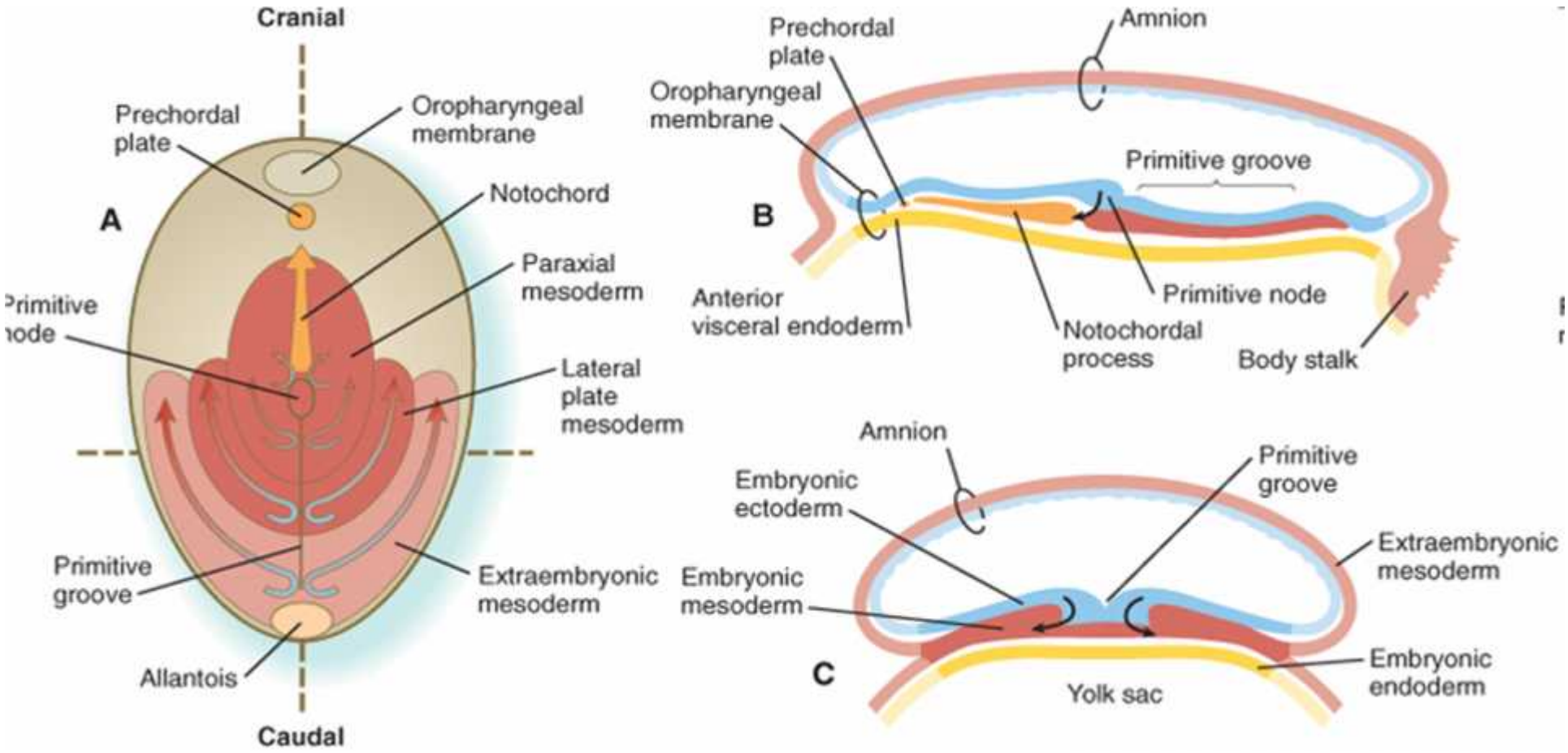

- Primitive node positions primitive streak for gastrulation, induces neural differentiation
- AVE from primitive endoderm secretes factors that position primitive streak in posterior, induce head formation

The node also sets up the neural plate

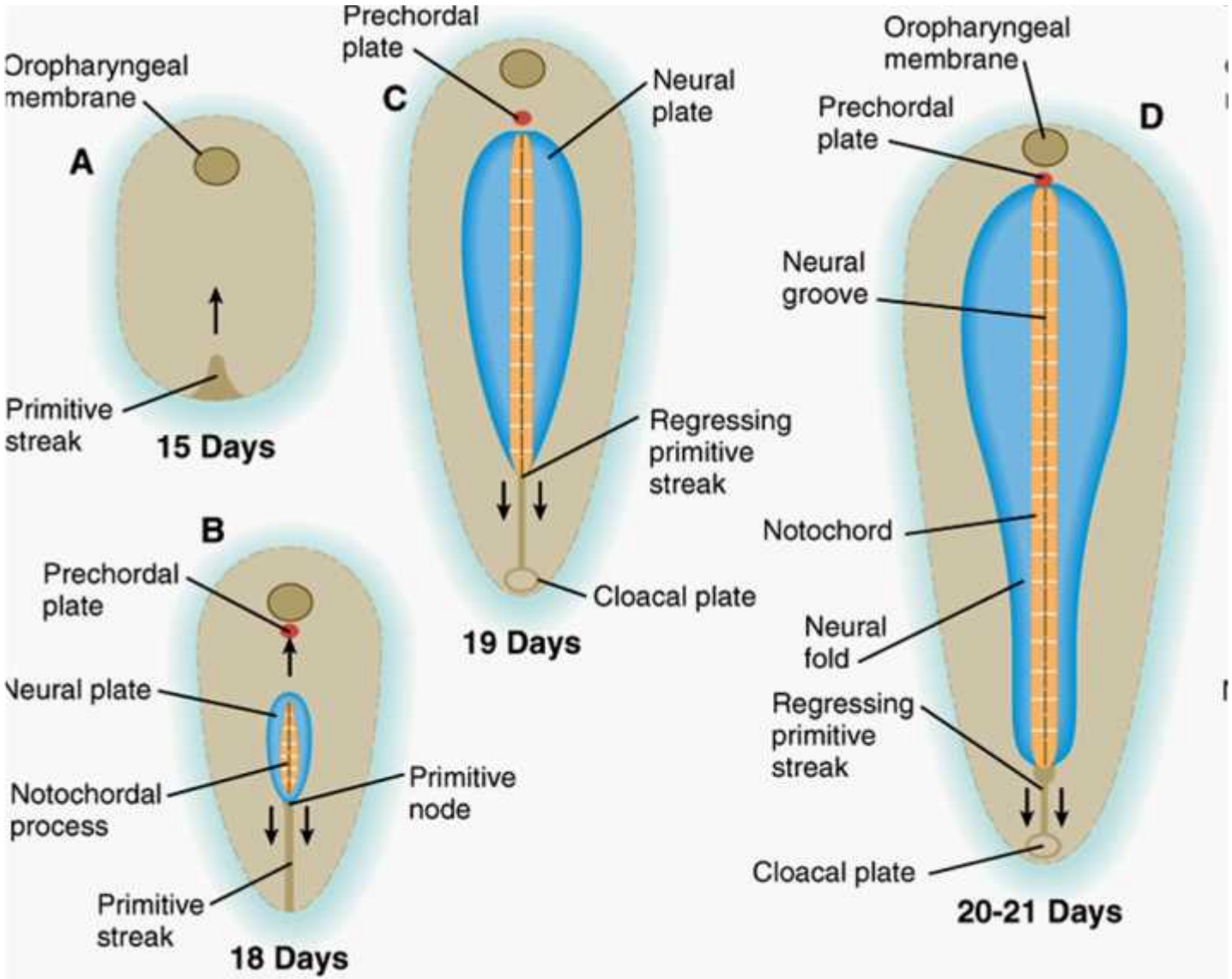

Head signaling centers

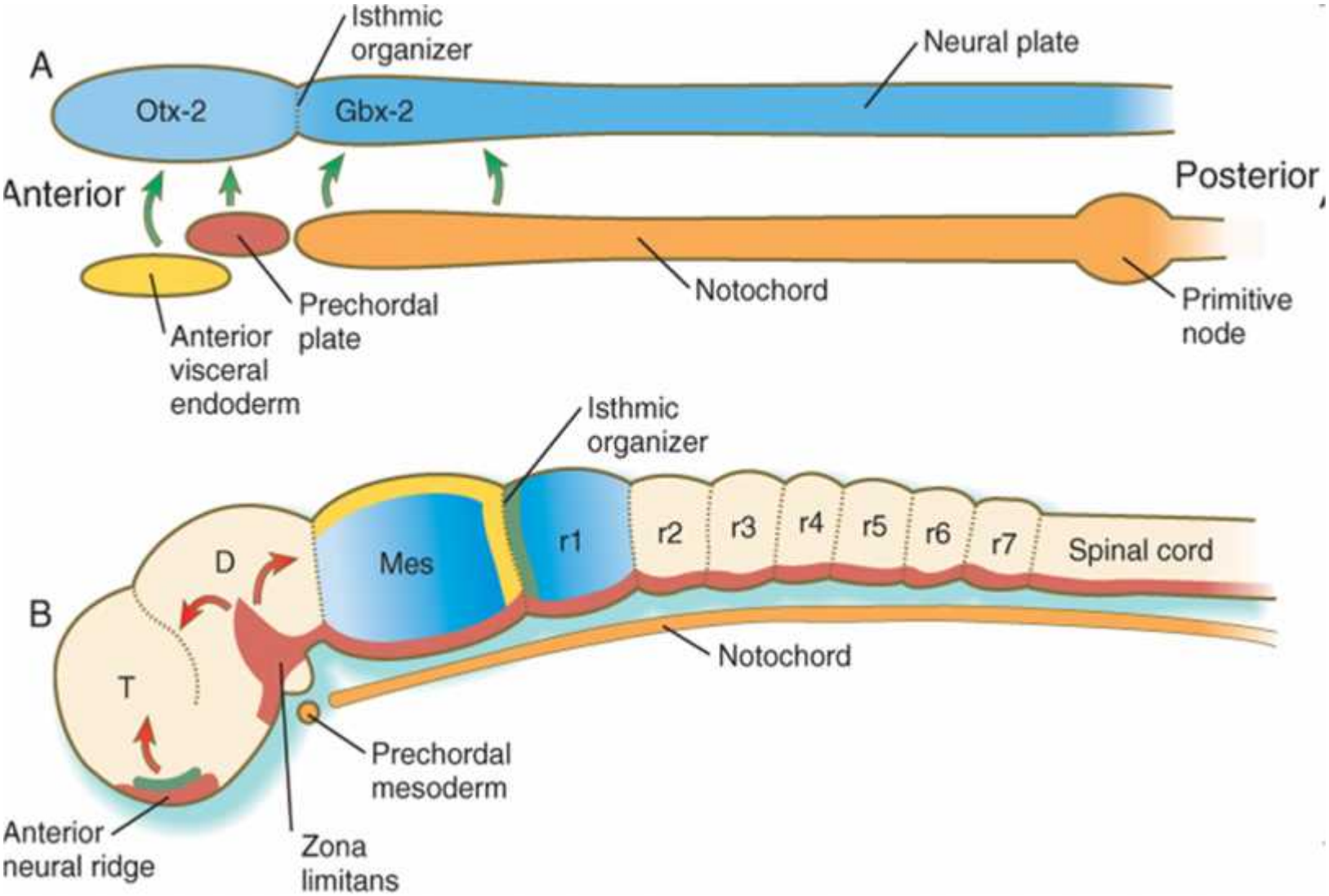

Prechordal plate~ early notochord

Left-Right asymmetry is established at gastrulation

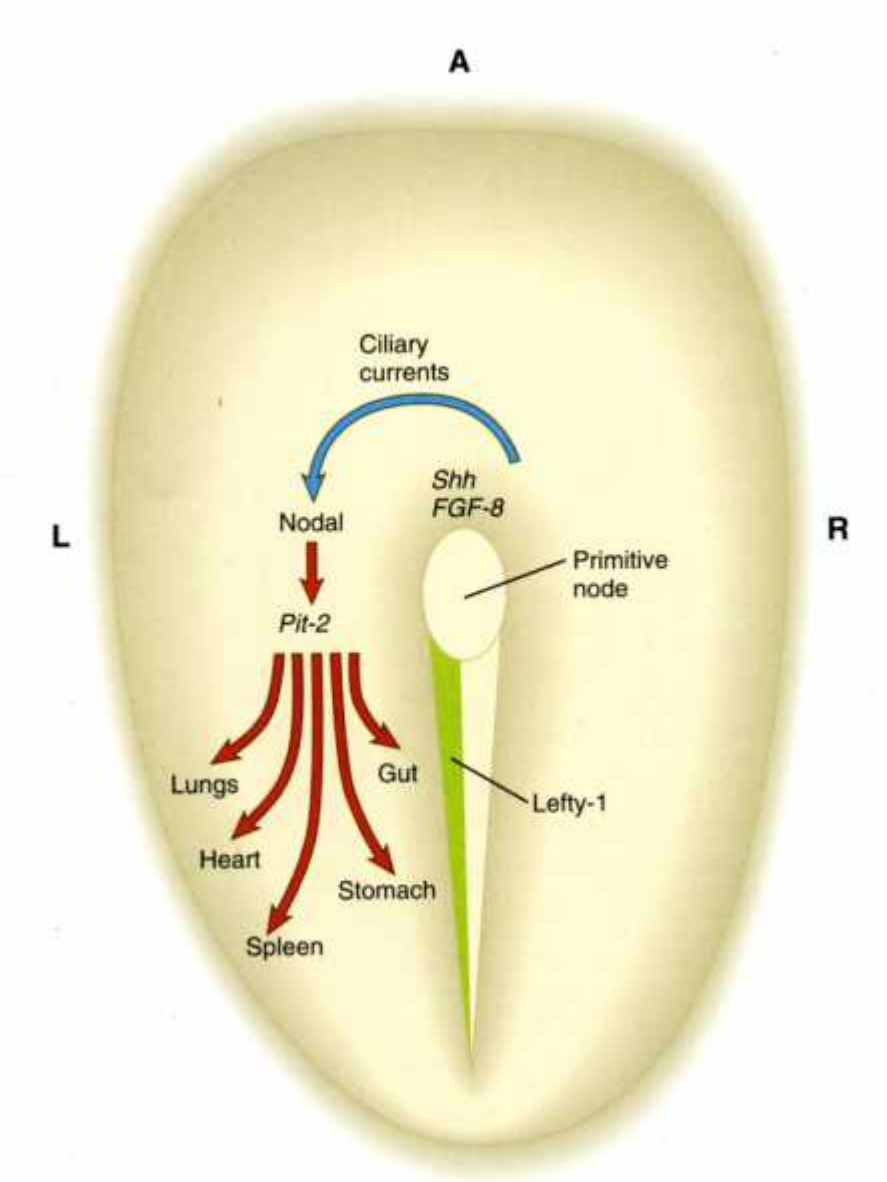

Leftward beating of cilia at node moves secreted molecules sonic hedgehog (Shh) & FGF-8 to the left side of embryo.

Causes left side genes Nodal and Pitx2 to be expressed which then pattern developing organs.

If cilia are defective, Shh and Fgf8 can randomly end up on right side, resulting in reversal of symmetry, aka ***situs inversus*** (liver on the left, spleen on the right, etc.)

Situs can be complete (everything reversed) or partial (only some organs reversed).

Situs Inversus

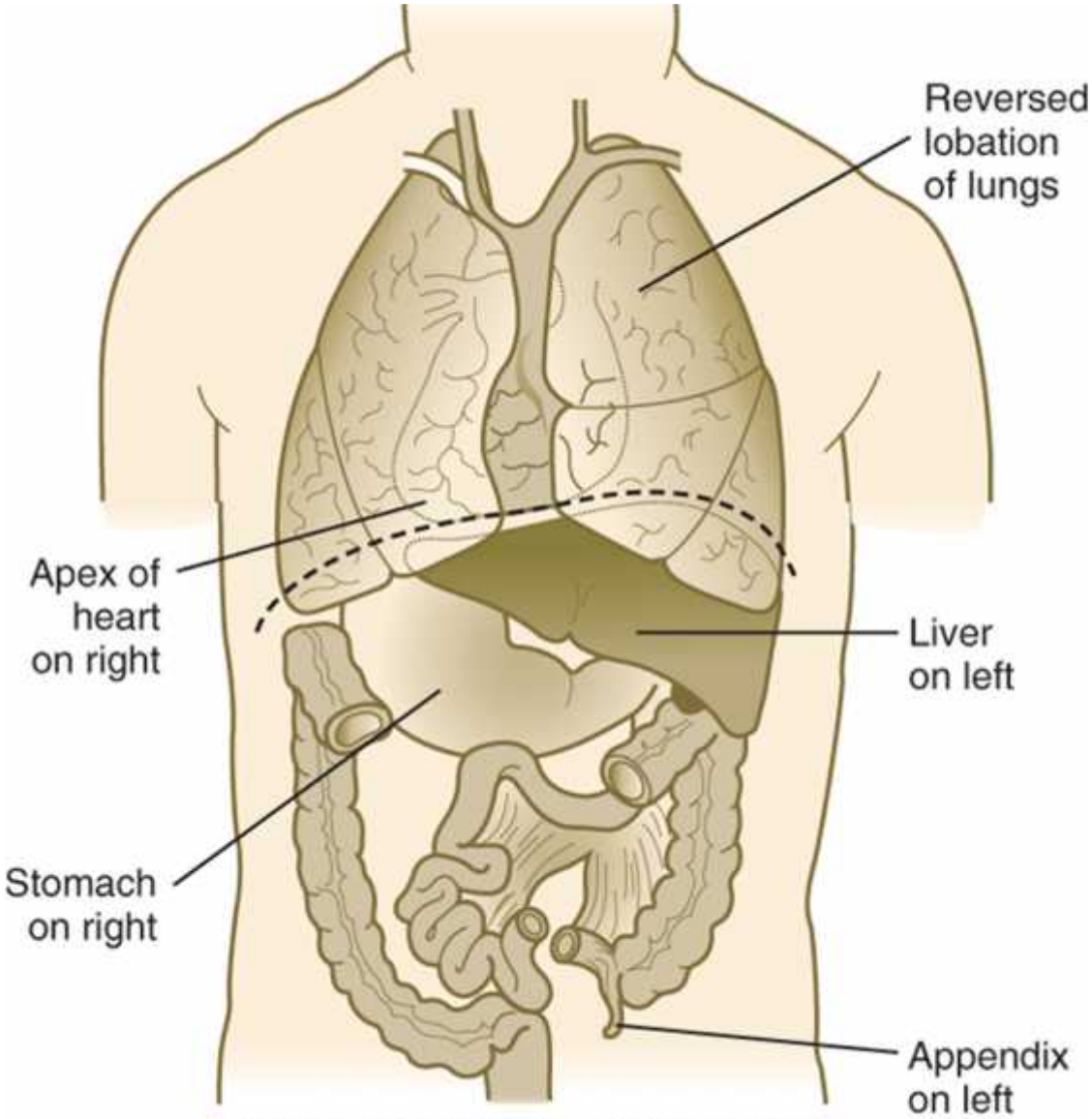

What happens if there is “not enough” gastrulation?

Caudal agenesis (sirenomelia)

Premature regression of the primitive streak leads to widespread loss of trunk and lower limb mesoderm.

VATeR association:
Vertebral defects
Anal atresia
Tracheo-esophageal fistula
Renal defects

VACTeRL association:
those above plus…
Cardiovascular defects
Limb (upper) defects

What happens if there is “too much” gastrulation?

Sacrococcygeal teratoma

If the primitive streak fails to regress, multipotent primitive streak cells can develop into multi-lineage tumors (containing ecto-, meso-, and endodermal tissues).